

Study of direct immunofluorescence in various connective tissue disorders

Krishnendra Varma¹, Megha Sharma^{2,*}

¹Professor & HOD, ²PG Student, Dept. of Dermatology, RD Gardi Medical College, Ujjain, Madhya Pradesh

***Corresponding Author:**

Email: msharma1138@gmail.com

Abstract

Introduction: Connective tissue diseases (CTDs) have got significant cutaneous manifestations that may exhibit widespread systemic dysfunction. Direct immunofluorescence (DIF) test for tissue bound autoantibodies provides a useful investigative tool for the diagnosis of connective tissue diseases.

Aim: The aim of the study was to see the clinical, histological and immunological correlation of various connective tissue diseases and to evaluate the sensitivity of DIF in specific diagnosis of various CTDs.

Materials and Method: 21 patients of CTDs attending skin OPD and IPD of a tertiary care hospital in Ujjain were included in the study and were thoroughly examined.

Results: Out of 21, 15 cases showed DIF patterns concordant with histologic diagnosis. The sensitivity of DIF was 88.9% (8/9) in the cases of DLE (Discoid lupus erythematosus), 66.6% (2/4) in SLE (Systemic lupus erythematosus) and 62.5% (5/8) in Scleroderma.

Conclusion: DIF is essential for diagnosing connective tissue diseases with the clinical and the histopathological overlap as well as in monitoring the prognosis of the diseases.

Keywords: Direct Immunofluorescence, Connective Tissue Diseases, Histopathology, Sensitivity, Diagnosis

Introduction

Connective tissue diseases (CTDs) are a group of clinical disorders that have an underlying autoimmune pathogenesis. As with many autoimmune diseases, CTDs display a strong predilection for women, ranging from 2:1 up to 15:1 female predominance with racial background occasionally playing a role in either the severity or prevalence of the disease.⁽¹⁾ Immunohistology, serology in conjunction with histology, aid in delineating and diagnosis of various skin disorders with systemic involvement e.g. Systemic Lupus Erythematosus. Immunofluorescence (IF) studies have now become an invaluable diagnostic adjunct to clinical and histological examination in various dermatological diseases. The ideal site for the biopsy specimen depends on the type of disorder being subjected to DIF, e.g. lesional in connective tissue diseases. Over the last fifteen years, examination of skin biopsy by immunofluorescence technique has progressed from a research tool to a routine diagnostic procedure of considerable value. The findings are pathognomic in various connective tissue diseases like DLE, SLE, SCLE and other dermatological conditions. But further research will definitely lead to better understanding of their pathogenesis. The diagnostic specificity of clinical findings varies among different connective tissue disorders. Clinical overlap is seen among different groups of cutaneous diseases. The greatest diagnostic accuracy is ensured by co-relating clinical, histological and immunofluorescence findings.⁽²⁾

The connective tissue diseases are grouped as systemic and discoid lupus erythematosus, systemic sclerosis, localized and generalized morphea,

dermatomyositis, rheumatoid arthritis and Sjogren's syndrome.⁽³⁾ This technique (DIF) will help in the specific diagnosis and confirmation of clinically diagnosed cases for the better management or treatment and it will also help in finding the severity of the diseases by predicting the deposition of immunoglobulins.

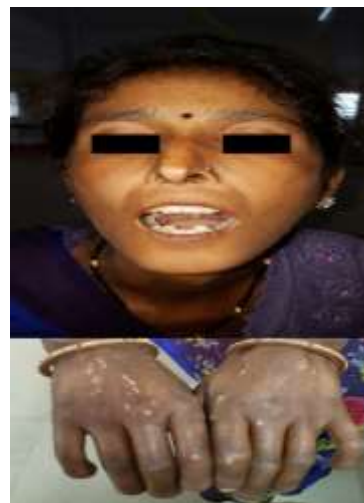Materials and Method

The present study was carried out in a tertiary care hospital in Ujjain, M.P. A total of 21 cases clinically diagnosed as connective tissue disease patients attending the Out Patient Department or admitted in ward constituted the subject material for the present study. A detailed history of each case was taken. Cases were thoroughly examined and routine investigations were sent. Biopsies were sent for histopathological and DIF studies and on the basis of clinical, histopathology and DIF findings correlation between the three was seen. Analysis was done by using SPSS (Statistical Package for the Social Sciences) software and necessary test of significance (McNemar's test) was applied. Specific treatment was given to the patients and they were asked to come for follow-up.

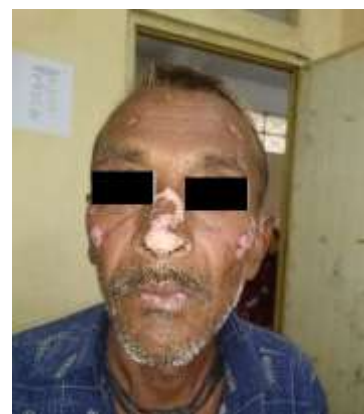Results

In the present study the most common connective tissue disease was found to be DLE, 09(43%). The age of patients ranged from 25 years to 85 years. Maximum no. of cases of Discoid Lupus Erythematosus 7(78%) were seen in the age group of 26-65 years, Systemic Lupus Erythematosus 3(75%) was seen between the age group of 26-45 years while most of the cases of Scleroderma 6(75%) were seen in 3rd decade of life.

The majority of patients were males in case of DLE and females preponderance was seen in SLE and Scleroderma. Most of the lesions of Discoid Lupus Erythematosus 6(67%) occurred on face & scalp, while lesions of Systemic Lupus Erythematosus were seen on face & upper extremities in maximum no. of patients 4(100%). Discoid Lupus Erythematosus patients presented with plaques & scales while hyperpigmented macules were observed in Systemic Lupus Erythematosus patients and all the cases of Scleroderma showed hide bound skin & macules. Carpet tack sign was seen in 6 (67%) of Discoid Lupus Erythematosus cases, malar rash was present in 3(75%) cases of Systemic Lupus Erythematosus and Raynaud's Phenomenon with sclerodactyly & Hide Bound Skin was noted in (7)87% cases while Sclerodactyly with Hide Bound Skin was seen in 2 (25%) of the cases of scleroderma. The study showed 7(78%), 4(100%) & 5(62%) positive ANA in Discoid Lupus Erythematosus, Systemic Lupus Erythematosus & Scleroderma respectively. IgG was seen in maximum number of cases 18(85.7%), IgG & C3 deposits were seen 11(52%) and IgM was observed in 12(57%). Out of 6 DIF negative cases 1 was DLE, 2 were of SLE and 3 of Scleroderma. Histopathological diagnosis of various connective tissue diseases along with corresponding DIF findings are depicted in Table 1. DIF was diagnostic in almost all the cases DLE and also helped to confirm the diagnosis of SLE and Scleroderma. The statistical analysis of DIF is shown in Table 2.



Case- Scleroderma



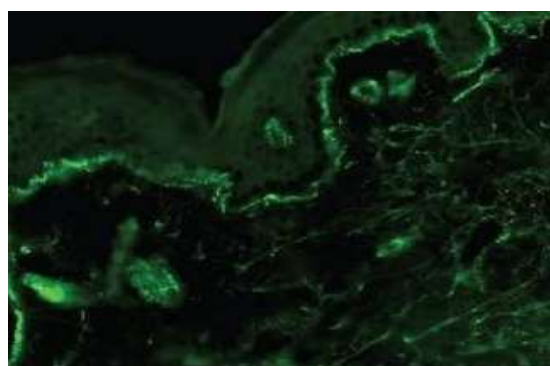
Case-DLE

Table 1: Histopathological diagnosis & DIF findings of connective tissue diseases

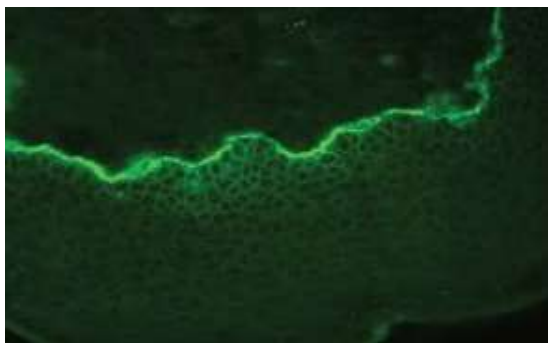
Histopathological diagnosis	DIF Positive no. of cases	DIF negative no. of cases	Total no. of cases (%)
DLE	08	01	09(43%)
SLE	02	02	04(19%)
Scleroderma	05	03	8(38%)
Total	15	06	21

Table 2: Statistical Analysis

Histopathological diagnosis	Sensitivity (%)	Specificity (%)	PPV (%) (Positive Predictive Value)
DLE	88.9%	97.5%	88.8%
SLE	66.6%	97.8%	66.6%
Scleroderma	62.5%	100%	62.5%



DIF of DLE



DIF of Scleroderma

Discussion

Although Connective tissue diseases (CTDs) are multisystem disorders, the skin is often the presenting sign. Interestingly, the clinical spectrum of presentation for CLE (cutaneous lupus erythematosus) and Scleroderma can vary from skin only to internal organ only. This offers the clinician a diagnostic challenge and it is thus critical that dermatologists maintain a heightened awareness of non-skin manifestations when working up patients for CTD. Furthermore, the wide array of clinical signs within each disease makes absolute classification of CTDs exceedingly difficult, especially in cases of overlap.⁽⁴⁾

DIF has played an important part in the diagnosis and prognosis of such diseases. Hence the present study was undertaken to analyze the co-relation between the clinical, histopathological and DIF findings in various connective tissue diseases of the skin and also to determine the impact of direct immunofluorescence on diagnosis.

In our study, DLE was found to be the most common disease with 9(43%) cases followed by 4(19%) cases of SLE and 8(38%) cases of scleroderma. These observations are comparable to the findings of other studies done by Ranjana Walker Minz et al(2010),⁽⁵⁾ Roseli Svartman Isfer et al(1996),⁽⁶⁾ Kulthanan K et al(2006),⁽⁷⁾ H. Vinma Shetty et al(2012),⁽⁸⁾ where DLE was the most common connective tissue disease.

Systemic Lupus Erythematosus was observed majorly between the age group of 26-45 years(75%), DLE patients aged between 25-65years(78%) and Scleroderma was seen in 3rd decade of life. Age distribution of present study is comparable with the studies of Roseli Svartman Isfer et al(1996)⁽⁶⁾ and H. Vinma Shetty et al(2012)⁽⁸⁾ having more or less similar findings.

Out of 9 patients of DLE 5(55%) were male and 4 (45%) were females which contrasts with the studies done by Dr. Sandeep Kodali et al⁽⁹⁾ showing female preponderance. All the cases of SLE and Scleroderma were females which correlates with the studies done by Dr. Sandeep Kodali et al⁽⁹⁾ and Roseli Svartman Isfer et al(1996).⁽⁶⁾

The above study shows that Discoid Lupus Erythematosus patients presented with plaques & scales which correlates with the study done by Ye Won Han et al,⁽¹⁰⁾ while hyperpigmented macules were observed in Systemic Lupus Erythematosus patients. All the cases of Scleroderma showed hide bound skin & macules and these observations are consistent with literature.

In 6(67%) cases of DLE the lesions were observed over face and scalp which is concurrent with the study done by Ye Won Han et al⁽¹⁰⁾ and Fahad M. Al Saifet al⁽¹¹⁾ which also proves that most of the DLE lesions occur over face and scalp and has relation with UV rays. Lesions of Systematic Lupus Erythematosus were seen on face and upper limbs in max. no. of patients 4(100%) and most of the patients of scleroderma presented the lesions over face and extremities which is mentioned in literature.⁽¹²⁾

The present study showed 7(85%), 4(100%) & 5(62%) positive ANA in Discoid Lupus Erythematosus, Systematic Lupus Erythematosus & Scleroderma respectively and this correlates with the study done by Dr. Sandeep Kodali et al⁽¹¹⁾ which showed ANA positivity in 66.6% of DLE, 87.5% of SLE and 83.3% of scleroderma cases.

The present study shows IgG deposition in 100% cases of DLE, SLE and 62.5% cases of scleroderma (at BMZ). IgM deposition is seen in 100% cases of SLE and 25% cases of scleroderma (at BMZ). IgG and C3 deposits together were seen in 89% cases of DLE and 25% cases of scleroderma (at BMZ). Our results are more or less similar to the study done by Roseli Svartman Isfer et al(1996).⁽⁶⁾ Subepidermal homogeneous and thread patterns in DLE were observed.

The clinico-histological and histological-immunological concordance was tested using McNemar's test of significance. It was found that histopathology and DIF gave comparable results, that is, the difference in results by two methods was not statistically significant (P= 0.5). Comparison of clinical and histopathological results (clinico-histological concordance), showed p value of 0.5 which again indicated good concordance.

In the present study, histopathology was taken as gold standard since the results were consistent. In many situations, a negative DIF result was also important since it helped to exclude an immune basis for the disease, even though it could not provide a precise diagnosis. There were no false-positive DIF results. Histopathology was conclusive in 20 cases.

In our study, out of 9 cases of DLE, results of DIF and histopathology correlated well in 8 cases, while in case of scleroderma, out of 8 cases DIF and histopathology showed concurrent results in 5 cases. In cases of DLE, SLE, and scleroderma the sensitivity was 88.9%, 66.6% and 62.5% respectively. The P value in all the cases was 0.5, which was insignificant and showed correlation of findings of the two methods. Out

of 4 cases of SLE histopathology was inconclusive in 1 case and was diagnosed on the basis of results of DIF, which was conclusive of SLE. The above results are comparable with the studies done by Vijaya V Mysorekar et al⁽¹³⁾ and Lebe et al⁽¹⁴⁾ showing 100% sensitivity in DLE cases.

Hence, at times a diagnosis based solely on the clinical or histologic findings may not be accurate and at such points DIF is extremely helpful in confirming a suspected diagnosis and to discern among closely related cases.

Conclusion

Direct Immunofluorescence (DIF) testing is one of the several parameters needed to diagnose patients with connective tissue skin disorders. Some DIF findings are characteristics or diagnostic while others have a differential diagnosis and require a thoughtful clinicopathological correlation or further testing to establish a correct diagnosis.

Our study concludes that the DIF is essential for diagnosing autoimmune connective tissue diseases with the clinical and the histopathological overlap. The best approximation to the goal of improving diagnostic specificity will be achieved by detailed correlation of findings of histological findings, immunological findings and clinical history. Therefore, immunofluorescence can be considered as the gold standard for investigating connective tissue diseases. This study gives the conclusion that the direct immunofluorescence is an essential tool for diagnosing connective tissue diseases of skin.

References

1. Zhou X, Tan FK, Wang N, et al. Genome-wide association study for regions of systemic sclerosis susceptibility in a Choctaw Indian population with high disease prevalence. *Arthritis Rheumatology*, 2003; Volume 48, Issue 9, September 2003; Pages 2585–92.
2. Thomas RHM, Black MM, Bogal B. The value of Immunofluorescence techniques in the diagnosis of skin disorders. In: Anthony BP and Mac Sween RNM, editors. *Recent advances in Histopathology – 12*. Churchill Livingstone, Edinburgh 1984: 69-81.
3. Goodfield MJD, Jones SK, Veale DJ. The connective tissue diseases. In: Burns T, Breathnach S, Cox N, Griffiths C, editors. *Rook's Textbook of Dermatology* 8th ed Oxford; Wiley – Blackwell Scientific Publications, 2010 P. 51.1-51.138.
4. Reddy BY, Hantash BM. Cutaneous Connective Tissue Diseases: Epidemiology, Diagnosis, and Treatment, *Open Dermatol J*. 2009 Jan 1;3(1):22–31.
5. Minz R W, Chhabra S, Singh S, Radotra BD, Kumar B. Direct immunofluorescence of skin biopsy: Perspective of an immunopathologist. 2010, Vol 76, Issue 2;150-57.
6. Isfer et al. Direct immunofluorescence in Lupus Erythematosus (LE), *Sao Paulo Medical Journal/RPM*, 1996;114(2):1141-47
7. Kulthanan K, Jiamton S, Taiyaitiang C, Pinkaew S, Suthipinittharm P. Direct immunofluorescence study in Thai patients with scleroderma. *J Med Assoc Thai*. 2006 Oct;89(10):1670-6.
8. Vinma Shetty H, Girish P N, Narendra Shetty J, A clinical study of skin changes in connective tissue diseases, *International Journal of A J Institute of Medical Sciences* 1,2012;147-51.
9. Kodali Sandeep , Reddy L.V.N , Lavanya M , Sravanthi K, Chary N.N, A Clinical Study of Connective Tissue Diseases, *MRIMS Journal of Health Sciences* 2015;3(2):150-55
10. Ye Won Han et al, Four Cases of Facial Discoid Lupus Erythematosus Successfully Treated with Topical Pimecrolimus or Tacrolimus, *Ann Dermatol*. 2010 Aug; 22(3):307–11.
11. Fahad M. Al Saif et al, Discoid lupus erythematosus in a Saudi population: Clinical and histopathological study, *Journal of the Saudi Society of Dermatology & Dermatologic Surgery*, 2012 Jan ;Vol 16: Issue 1:9–12.
12. George R, Mathew J. Autoimmune connective tissue diseases. In: *IAVDL Textbook of Dermatology*. 4th Ed; Mar. 2013. Bhalani Publishing house, Mumbai 2013; Vol 2:1714-33.
13. Mysorekar VV, Sumathy TK, Shyam Prasad AL. Role of direct immunofluorescence in dermatological disorders. *Indian Dermatol Online J* 2015;6:172-80.
14. Lebe B, GülNýflýođlu G, Seyrek S, Ellýdokuz H. Evaluation of clinical and histopathologic/direct immunofluorescence diagnosis in autoimmune vesiculobullous dermatitis: Utility of direct immunofluorescence. *Turk Patoloji Derg* 2012;28:11-6.