

A clinicomycological study of tinea capitis in South Karnataka

Raju J¹, Vignesh NR², Raghavendra KR^{3,*}

¹Associate Professor, ²Junior Resident, ³Senior Resident, Dept. of Skin & VD, MMCRI, Mysuru

***Corresponding Author:**

Email: rkrbmc@gmail.com

Abstract

Background: Tinea capitis is a superficial fungal infection in which scalp hair follicle are affected. It is most commonly seen among school going children. Now a days there is a drastic emergence of resistance to antifungal treatments and also we are observing changing trend in pattern and causing organism.

Objectives: The present study was conducted to identify and classify the prevalent clinical pattern of tinea capitis in our region and to define the spectrum of dermatophyte species causing the tinea capitis in our region.

Materials and Method: After taking informed written consent from the parents or the guardian, 100 new clinically diagnosed cases of tinea capitis were taken for the study over a period of 12 months from January 2015 to December 2015 in the Dermatology department, K.R Hospital, Mysore.

Results: The incidence of tinea capitis among the total outpatients was 4.27%. The most common age group affected was 6-10 years. A male to female ratio was 1.7:1. The most common clinical type was grey patch type (61%) followed by black dot type (18%), seborrhoeic type (13%) and kerion (8%). KOH was positive in 85% cases and culture was positive in 43% of the cases. The organisms isolated were *Microsporum gypseum* in 19 cases (44.1%), *Trichophyton violaceum* in 17 cases (39.53%), *Trichophyton rubrum* in 5 cases (11.6%), *Microsporum audouinii* and *Trichophyton tonsurans* one case each.

Conclusion: Tinea capitis is most commonly caused by *Microsporum gypseum* in our region. It will be very useful to do a direct microscopic examination and culture on every cases of tinea capitis, so that we can isolate the species and we can identify the any rare organism causing Tinea capitis.

Keywords: Tinea capitis, Black dot, Grey patch, *Trichophyton rubrum*, *Microsporum gypseum*.

Introduction

Tinea capitis is the fungal infection of the scalp in which the essential feature will be invasion of hair shafts by a dermatophyte fungus usually.⁽¹⁾ Tinea capitis is most commonly seen in children age group of 3 to 14 years.⁽²⁾ Tinea capitis can be transmitted via infected persons, their fallen infected hairs and some time through selected animal vectors.⁽³⁾ The incidence of Tinea capitis varies from 0.5% to 10% as seen by different.⁽⁴⁾ In USA *Trichophyton tonsurans* is currently the most common cause of tinea capitis while *Trichophyton violaceum* has become a major cause of tinea capitis in Europe and also in India.⁽⁵⁾ Anthropophilic organisms *Trichophyton tonsurans* and *Trichophyton violaceum* are presumed to be associated with higher rates of asymptomatic carriage among children.⁽⁶⁾ This study was conducted to know the recent trends in the epidemiology and causative dermatophyte species of the disease as there are very few studies were conducted in the recent past.

Materials and Method

This study is a prospective cross-sectional, was conducted in the department of Dermatology, MMCRI, Mysore in collaboration with the Department of Microbiology. Total 100 new clinically diagnosed cases of tinea capitis were enrolled in the study over a period of 12 months from January 2015 to December 2015. A detailed history was taken and dermatological examination included clinical type of tinea capitis with

areas of involvement on scalp, extent of involvement, screening of dermatophyte infection over other areas of skin & nails were done and noted. We also looked for Presence of regional lymphadenopathy. The siblings and other family members were also screened for tinea capitis and other dermatophytosis.

The scalp scrapings were collected from the margins of the lesions with a sterile surgical blade, from at least two different areas of scalp. The affected dull and lustreless hairs were epilated with the help of a sterile epilators. All the specimens were collected in a clean sterile paper. Direct microscopic examination of the scrapings and hairs was carried out by mounting with 1-2 drops of 10%-20% KOH for 15-30 minutes. The remaining material was sent to the department of Microbiology where it was inoculated into Sabouraud dextrose agar (SDA) with chloramphenicol, cycloheximide and gentamycin and also selected culture in Dermatophyte test media (DTM). The microscopic characteristics of the culture material were studied using Lactophenol cotton blue mounts by both Microbiologist and Dermatologist.

Results

The incidence of tinea capitis in our study was 4.27% of our routine OPD. The majority of cases were Male childrens (63%) compared to females (37%). The male children to female ratio was 1.7:1. The predominantly involved age group was 6-10 years (56%) and the least in those more than 10 years

(8%)[Table 1]. Incidence of tinea capitis was higher in children from rural back ground areas (53%) compared to 47% in the urban areas, though much difference was not observed. Majority of the cases (49%) belonged to lower socioeconomic status followed by lower middle class who contributed to 30% of the cases. Middle class contributed to 12% cases. In this study the number of cases residing in hostel was significantly lower (18%) than the non-hostel residents. Out of 18 residents of hostel, history of contact was present in 13 cases (72%), which is significant compared to 82 non-hostel residents, of which 9 only had history of contact (10.9%). In our study, the non-inflammatory type of tinea capitis (Table 2) was most common compared to inflammatory type. In the non-inflammatory type, grey patch variant was the most common type seen in 61% of the cases, followed by black dot type in 18% of the cases. Seborrhoeic type of T capitis was seen in 13% of the cases. In the inflammatory type, kerion was seen in 8% of the cases. (Fig. 1) Out of 100 cases subjected to wood's lamp examination, only 3 cases showed green fluorescence, the cases belonged to grey patch type and showed ectothrix type of hair shaft involvement. Direct microscopy examination (Table 3) was done for all 100 cases, of which 85% were KOH positive and (Fig. 2) 15 were negative. In this study endothrix was seen in 54 cases and ectothrix was seen in 31 cases. Out of 100 cases in the study, 43 cases showed positive culture results. we compared both direct microscopy and culture results we found, 39% of the cases were both culture and KOH positive, 46% were KOH positive and culture negative, 11% were both KOH and culture negative and 4% were KOH negative and culture positive. Out of 43 culture positives (Table 4) *Microsporum gypseum* was isolated in 19 cases (44.1%) (Fig. 3, 4) and *Trichophyton violaceum* in 17 cases (39.53%). *Trichophyton rubrum* was isolated in 5 cases (11.6%) (Fig. 5) and *Microsporum audouinii* and *Trichophyton tonsurans* were isolated one case each. The major clinical pattern caused by *Microsporum gypseum* was grey patch type in 11 cases followed by kerion in 5 cases. *Trichophyton violaceum* caused black dot type in 8 cases, grey patch in 4 cases and seborrhoeic type in 5 cases. *Trichophyton rubrum* was seen in 4 cases of grey patch type and in 1 case of black dot type. *Trichophyton tonsurans* was seen in 1 case of grey patch type and *Microsporum audouinii* in 1 case of grey patch type.

Table 1: Age and sex distribution

Age (in Years)	Males	Females	Total
<5	23	13	36
6 to 10	32	24	56
11 to 15	8	0	8
Total	63	37	100

Table 2: Distribution of cases as per the clinical type

Clinical Type	Number (Percentage)
Grey Patch	61 (61%)
Black Dot	18 (18%)
Seborrhoeic	13 (13%)
Kerion	8 (8%)

Table 3: Direct microscopy examination results

KOH	Number (Percentage)
Positive	85 (85%)
Negative	15 (15%)

Table 4: Organisms grown on Culture

Organism	Number (Percentage)
<i>Microsporum audouinii</i>	1 (2.32%)
<i>Microsporum gypseum</i>	19 (44.1%)
<i>Trichophyton rubrum</i>	5 (11.6%)
<i>Trichophyton tonsurans</i>	1 (2.32%)
<i>Trichophyton violaceum</i>	17 (39.53%)

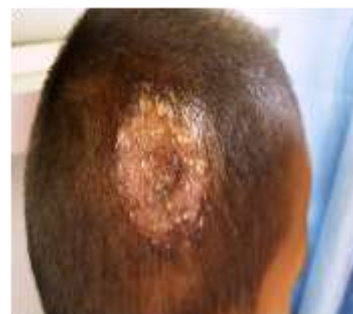

Fig. 1: Kerion- Inflammatory boggy swelling with pustules

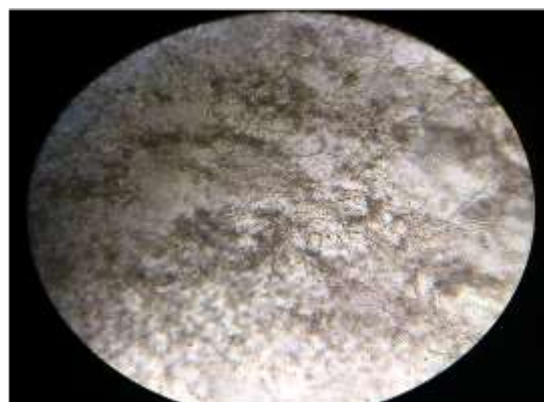

Fig. 2: KOH positive shows branched hyphae

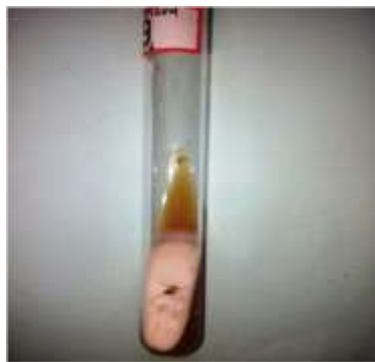

Fig. 3: Dermatophyte Test media shows positive culture of microsporum species

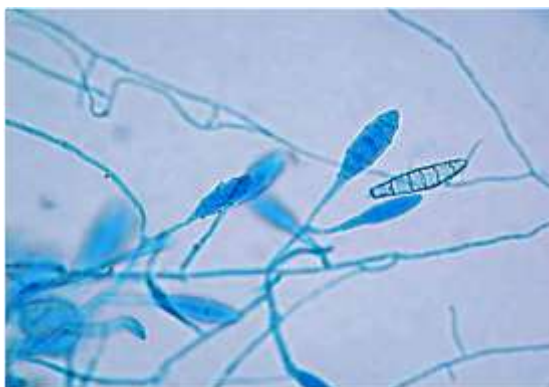


Fig. 4: Lactophenol cotton blue mount showing macroconidia of Microsporum gypseum

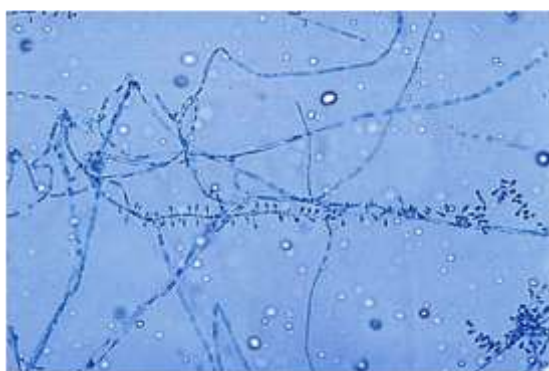

Fig. 5: Lactophenol cotton blue mount showing microconidia of Trichophyton rubrum

Discussion

The total incidence of tinea capitis during the study period was 4.27% and almost similar results were observed by Kalla G et al⁽⁷⁾ and El-Khalawany M et al.⁽⁸⁾ The incidence of T capitis varies from 0.5% to 10% as reported by other studies. Such variations may be due to difference in selection of cases, geographical variation, and difference in socio-economic status, cultural factors. Even the patients who attend the outpatient department do not exactly reflect the true incidence of tinea capitis in community as it is seen in a study done in Cleveland⁽⁹⁾ that 60% of the cases were in a carrier state. In this study, majority of the cases (56%)

were in 6-10 years age group, 36% of the cases were toddlers (1-5 years) and 8% of cases in 11-15 years age group. There were no cases of tinea capitis in neonates and infants. Sajjan AG and Mangalgi SS⁽¹⁰⁾ reported 52.9% in 5-10 years age group, which is almost similar to the present study. In our study males were slightly more affected when compared to females in a ratio of 1.7:1. Grover C et al⁽⁹⁾ in which 51.4% were females observed similar results. Kalla G et al⁽⁶⁾ also reported male to female ratio in their study to be 1.8:1 which is almost similar to the present study. The majority of cases (49%) in the present study were from lower socio- economic status, 30% belonged to lower middle class and 12% to middle class. Akinboro et al⁽¹¹⁾ obtained similar results in study in southwest Nigeria.

In this present study, history of contacts was present in 22% of the cases. Of these 22 cases, 13 cases (72%) gave history of contacts in hostel and the rest 9 cases (10.9%) gave history of contacts in their family members. In our study 18 cases gave history of contact with pet animals like cats and dogs. Most of the cases in this study came with clinical features of patchy loss of hair and scaling. The main complaint for which the case came to the hospital was alopecia. The most common clinical pattern observed in this study was grey patch (61%) followed by black dot (18%) then by seborrhoeic (13%) and 8% was kerion. Sajjan AG and Mangalgi SS⁽⁹⁾ also reported that grey patch (58.8%) as the commonest clinical type, followed by black dot (21.5%), kerion (13.7%) and seborrhoeic (5.8%) type. Out of 100 cases in this study 85 cases were KOH positive. This is in accordance to the result obtained by Grover C et al⁽¹²⁾ (82.3%), Amer Abu El-Enin et al⁽¹³⁾ (80%). Endothrix infection was commonly seen in this study. Grover C et al⁽¹¹⁾ observed that endothrix in 41.5% of the cases and ectothrix in 31.7% of the cases. Of the 100 cases of tinea capitis, positive cultures were obtained in 43 cases. Sajjan AG and Mangalgi SS⁽⁹⁾ reported positive culture in 43.13% cases, which is in accordance to the present study. The reason for low positivity can be due to usage of indigenous medications by the patient and also technical errors and also due to contamination during collection of sample. In the present study Microsporum gypseum was isolated in 44.1% followed by Trichophyton violaceum in 39.53%, Trichophyton rubrum in 5 cases (11.6%) and Trichophyton tonsurans and Microsporum audouinii one case each. This finding was unlike those of other studies in which Trichophyton violaceum was commonly isolated. Irfaan Akhter et al⁽¹⁴⁾ reported Trichophyton mentagrophytes was the commonest isolate (47.36%), followed by Microsporum gypseum (26.31%), Microsporum canis (15.78%) and Trichophyton rubrum (26.31%). They isolated Microsporum gypseum from 5 patients. Microsporum gypseum are usually transmitted from soil and can be secondarily transmitted by animals to humans. This shows that the distribution of the various etiological

dermatophytes, which cause tinea capitis, varies considerably with respect to the geographical factors and the specific population group. In the United States, *Trichophyton tonsurans* was reported as the most prevalent causative species in both children and young adults. The change of spectrum in the United States from *Microsporum audouinii* to *Trichophyton tonsurans* was explained by the sensitivity of *Microsporum audouinii* to griseofulvin treatment and the importing of *Trichophyton tonsurans* by people emigrating from geographic areas where that vector had been the prominent cause of tinea capitis. These studies may prove that tinea capitis is a classic example of the changing geographic patterns of dermatophytosis and prove the role of geographic distribution in modulating the fungal spectrum among the different populations.

Conclusion

Tinea capitis remains an endemic disease reaching variable epidemic proportion among children. The parents of the cases had little or no educational status because of which they resort to indigenous medications leading to scarring of scalp. It is still very useful to do a direct microscopic examination and culture in order to isolate the species, changing patterns of occurrence of different species & their association with clinical pattern, though the treatment modalities do not vary with different species. Further new studies are to be conducted to find the etiological agent in other dermatophyte infections in other districts surrounding Mysore.

References

- Hay RJ, Ashbee HR. Mycology. In: Burns T, Breathnach S, Cox N, Griffiths C (eds.), *Rook's Textbook of Dermatology*. 8th ed. Oxford: Wiley-Blackwell Publishing Ltd; 2010. p.36.1-36.93.
- Verma S, Heffernan MP. Fungal diseases. In: Wolff K, Goldsmith LA, Katz SI, Gilchrist BA, Paller AS, Leffell DJ (eds.), *Fitzpatrick's Dermatology in General Medicine*. 7th ed. New York: The McGraw-Hill; 2008. p.1807-1821.
- Pai VV, Hanumanthayya K, Tophakhane RS, Nandihal NW, Kikkeri NN. Clinical study of Tinea capitis in Northern Karnataka: A three-year experience at a single institute. *Indian Dermatol Online J* 2013;4:22-6.
- Amrinder JK, Dipankar De. Superficial Fungal Infections. In: Valia RG, Valia AR (eds.), *IADVL Textbook of Dermatology*. 3rd ed. Mumbai: Bhalani Publishing House; 2010. p.252-97.
- Elewski BE, Hughey LC, Sobera JO, Hay R. Fungal diseases. In: Bologna JL, Jorizzo JL, Schaffer JV (eds.), *Dermatology*. 3rd ed. Philadelphia: Elsevier Saunders Ltd; 2012. p.1251-84.
- Kundu D, Mandal L, Sen G. Prevalence of Tinea capitis in school going children in Kolkata, West Bengal. *J Nat Sc Biol Med* 2012;3:152-5.
- Kalla G, Begra B, Solanki A, Goyal A, Batra A. Clinicomycological study of tinea capitis in desert district of Rajasthan. *Indian J Dermatol Venereol Leprol* 1995;61:342-5.
- El-Khalawany M, Shaaban D, Hassan H, AbdAslam F, Eassa B, Shaheen I et al. A multicenter clinicomycological study evaluating the spectrum of adult tinea capitis in Egypt. *Acta Dermatovenerol APA* 2013;22:77-82.
- Ghannoum M, Isham N, Hajjeh R, Cano M, Al-Hasawi F, Yearick D, et al. Tinea capitis in Cleveland: Survey of elementary school students. *J Am Acad Dermatol* 2003;48:189-93.
- Sajjan AG, Mangalgi SS. Clinicomycological profile of tinea capitis in children residing in orphanages. *Int J Biol Med Res* 2012;3(4):2405-7.
- Adeolu O Akinboro, Olayinka A Olasode, Olaniyi Onayemi. The Pattern, Risk Factors and Clinico-Aetiological Correlate of Tinea Capitis Among the Children in a Tropical Community Setting of Osogbo, South-western Nigeria. *Afro-Egypt J Infect Endem Dis* 2011;1(2):53-64.
- Grover C, Arora P, Manchanda V. Tinea capitis in the pediatric population: A study from North India. *Indian J Dermatol Venereol Leprol* 2010;76:527-32.
- Amer Abu El-Enin, Mohamed Khedr, Alaa Abu El-Ata. Tinea capitis in Assuit Governorate (A clinical and mycological study). *The Egyptian Journal of Hospital Medicine* 2007;29:738-44.
- Bose S, Kulkarni SG, Akhter I. The incidence of tinea capitis in a tertiary care rural hospital – a study. *Journal of Clinical and Diagnostic Research* 2011;5:307-11.