

Comparative study of percutaneous collagen induction therapy and dermabrasion on post acne scars

Nithya Priyadharshini S¹, Geetha K^{2,*}

^{1,2}Assistant Professor, Dept. of Dermatology, SRM University, Chennai, Tamil Nadu

***Corresponding Author:**

Email: geetha_ragunath@hotmail.com

Abstract

Introduction: Acne is a self-limiting disease of pilosebaceous unit seen predominantly in adolescence, clinically characterized by papules, pustules, comedones, nodules and cysts and may result in scarring.

Aim and Objectives of the study: To compare the effectiveness of percutaneous collagen induction therapy versus dermabrasion in acne scars, and for monitoring the adverse effects during and after the procedure

Materials and Method: Thirty patients with acne scars divided in to two groups A and B Group A underwent microneedling with dermaroller of 1.5mm dm, with the principle of percutaneous collagen induction. Group B underwent dermabrasion with motor assisted dermabrader using a diamond fraize. The percentage of improvement was graded with paired t test.

Results: Among the 30 patients Group A 11 patients (73%) and 8 patients in group B (53%) showed significant reduction in acne scar grades. Rolling and boxcar type of scars responded well to both. In group B 3 patients had post inflammatory hyperpigmentation.

Conclusion To conclude both percutaneous collagen induction therapy and dermabrasion were effective in treating acne scars but results was better with microneedling and is easy to perform and have minimal adverse effects.

Keywords: Acne scars, Microneedling, Dermabrasion, Rolling acne scars, Boxcar scars

Key Messages: PCI (microneedling) and dermabrasion are cost effective and gives good results. The results of PCI were better when compared to Dermabrasion

Introduction

Acne is a chronic self – limiting inflammatory disease of the pilosebaceous units, seen mainly in adolescents, 80% of affected individuals were between puberty and 30 years of age, some degree of scarring will ensue in them.⁽¹⁾ Acne scars were associated with greater psychological burden than a variety of disparate chronic disorders. The levels of social, psychological, and emotional impairments in acne compare with chronic diseases such as asthma, epilepsy, diabetes, and arthritis.⁽²⁾ The impact of acne on Quality of life index is independent of gender and age, but shows some correlation with disease severity. There are various modalities for treating post acne scars like LASERS, fillers limiting factor is the cost other procedures like chemical peeling, chemical reconstruction of scars (CROSS) with trichloroacetic acid (TCA), dermabrasion, microneedling with dermaroller and microdermabrasion were cost effective treatments.

Microneedling provides collagen induction through controlled mechanical stimulation of the dermis resulting in softening of scars leading to realignment of old collagen bundles. There is complete preservation of the epidermis during the procedure.

Dermabrasion (DA) consists of sequential planning of the depressed scars with electrical and/ or manual abraders and allowing the wound to heal by secondary intention, so as to achieve a leveling effect to make the scar less conspicuous.

Both microneedling and Dermabrasion are cheaper and cost effective compared to other modalities.

The aim of this study is to compare the effectiveness of percutaneous collagen induction therapy (microneedling with dermaroller) versus dermabrasion (motor assisted dermabrader) in acne scars, and for monitoring the adverse effects during and after the procedure.

Materials and Method

This is a prospective randomized open labeled controlled study conducted in a tertiary care hospital for a period of one year from 2011 – 2012. From about 100 patients with acne scars about 30 patients with rolling and boxcar scars acne scars were selected and grouped into two group A microneedling and group B dermabrasion. The acne scars were classified according to Goodman and Baron grading (Table 1).⁽³⁾

Table 1: Goodman and Baron Grading of Acne Scars

Grading	Level	Clinical description
1	Macular	Erythematous, hyper or hypo pigmented
2	Mild	Mild atrophy or hypertrophy scars that may not be obvious at social distances of 50cm or greater and may be covered adequately by makeup or the normal shadow of shaved beard hair in men or normal body hair if extra facial
3	Moderate	Moderate atrophic or hypertrophic scarring that is obvious at social distances of 50cm or greater and is not covered easily by makeup or the normal shadow of shaved beard hair in men or body hair if extrafacial, but is still able to be flattened by manual stretching of the skin (if atrophic).
4	Severe	Severe atrophic or hypertrophic scarring that is evident at social distances greater than 50cm and is not covered easily by makeup or the normal shadow of shaved beard hair in men or body hair if extrafacial and is not able to be flattened by manual stretching of the skin

Each group underwent the procedure for four sittings with 4-6 weeks intervals between each sitting and photographed each month to grade the improvement.

Inclusion criteria: Patients between 15- 35 years of age with rolling and boxcar scars and who are willing for follow up and to take photographs were included.

Exclusion criteria: Patients with active acne and other active skin infections like herpes simplex, bacterial skin infections were excluded. Pregnant and lactating women, persons with scarring other than acne and patients having keloidal tendency and bleeding diathesis and patients with unrealistic expectations were excluded from the study. Patients who have taken isotretinoin within past 6 months also were excluded.

Study procedure

Priming: in both groups the patients were advised to apply topically vitamin A or vitamin C two weeks prior to the procedure. The area to be treated is anaesthetized with topical anaesthesia like EMLA. After about waiting period of 45 minutes, the area is cleansed.

Technique

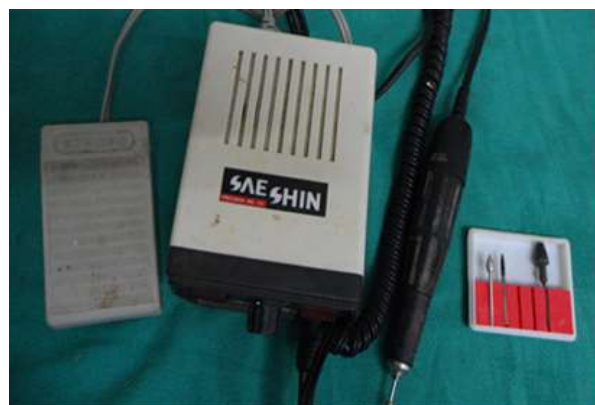Group A - Percutaneous collagen induction/microneedling

Instrument: Dermal roller - microarray of needles arranged circularly in 24 rows of 8 needles each making a total of 192 needles. The needles are gold plated and of 1.5 mm depth. 0.1 mm in dm (Fig. 1a).

Procedure The area to be treated is stretched with one hand with the other hand the instrument is to be held, and rolling is done in three directions perpendicular to each other. The end point is the appearance of minute pin point bleeding points. Entire procedure is completed in about 15 to 20 minutes. Sunscreen applied immediately patient is advised to avoid sun exposure for a week.

Group B – Dermabrasion

Instruments: Electrical dermabrader or hand engine 10,000 – 25000 rpm. Diamond fraizes Wire brushes and electrical/ motor dermabrader (Fig. 1)

**Fig. 1: Dermabrader**

Procedure: The skin is stretched with one hand. The hand piece of the electrical dermabrader is grasped firmly and is performed in a direction perpendicular to the axis of rotation of the diamond fraize. The dependent area is abraded till the appearance of firmer surface with increased large bleeding points and breaks in parallel lines.^(4,5) Individual scars were dermabraded with pear shaped fraize. Complete haemostasis achieved by applying ice cold saline sponges. Area is cleansed thoroughly with normal saline to remove remnants of epidermis. Dressing is done with non-adhering chlorhexidine gauze. Post-operative antibiotics, analgesics were prescribed. After healing the patients were advised to apply sunscreen regularly.

Serial photographs taken one before initiation of treatment and then repeated every month for all patients.

At the end of the fourth session the percentage improvement in acne scars was noted. The results were tabulated. These were graded on the basis of the

percentage improvement as follows: Grade 0: Less than 25% improvement; Grade 1: 25-49% improvement; Grade 2: 50-74% improvement; Grade 3: More than 75% improvement. Those patients with 1, 2 and 3 grades of improvement were taken to have improved. The percentage of those patients with improvement in group A and group B were compared using the students "t" test. The p value was computed. Patients were also asked to fill a questionnaire based on a 10-point scale starting from 0-10 to determine their life quality index.

Observation and Results

Of the 30 acne scar patients 15 had rolling scars, 11 had boxcar scars, 4 of them had both rolling and boxcar scar. In microneedling 67% of them were males and in dermabrasion approximately 80% of patients were males.

Group A – Microneedling. Among the 15 patients in group A, one patient showed less than 25% improvement at the end of the 4th session. Three patients showed improvement between 25-49%, 7 patients showed improvement between 50-75% and 4 patients showed improvement of more than 75% (Fig. 2a and 2b).

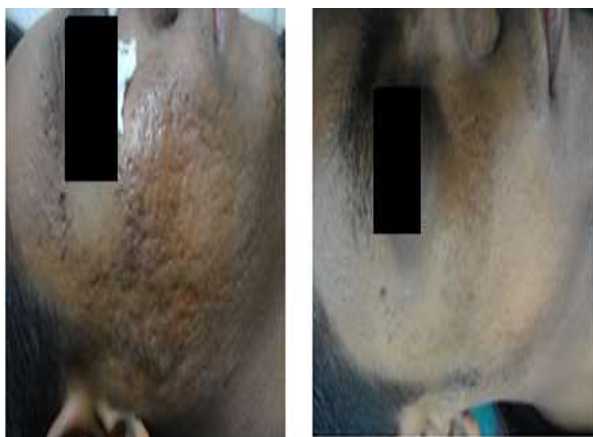


Fig. 2a and 2 b: Pre and post images of microneedling (grade 3 improvement)

The percentage of patients showing various grades of improvement is shown in Table 2. Out of the fifteen patients included in the study only one patient experienced severe erythema which persisted for more than 24 hours, subsided in 36 to 72 hours. Five had moderately severe erythema which subsided in about one day; 4 had mild erythema. Edema was present in almost all the patients which subsided in about 48 hours.

Table 2: Quartile grading and DLQI scales of Microneedling

		Micro-Needling	
		N	%
Gender	Male	10	66.7
	Female	5	33.3
Types of scars	Rolling	8	53.3
	Boxcar	7	46.7
	Boxcar, Rolling	0	0.0
Quartile grading scale	Grade 0, <25%	1	06.6
	Grade 1, 26–50%	3	20.0
	Grade 2, 51–75%	7	46.6
	Grade 3, > 75%	4	26.7
Dyschromia	Negative	9	60.0
	Positive	6	40.0
Erythema	Negative	4	26.7
	Positive	11	73.3
DLQI	Before	10.8	
	After	5.07	

Group B – Dermabrasion: Among the 15 patients in group B who underwent dermabrasion, at the end of 4 sessions, 3 patients showed less than 25% improvement. 7 patients showed improvement between 25-49%. 3 patients showed an improvement of 50-74% in their acne scars (Fig. 3a and b). 2 patients showed an improvement of more than 75%.

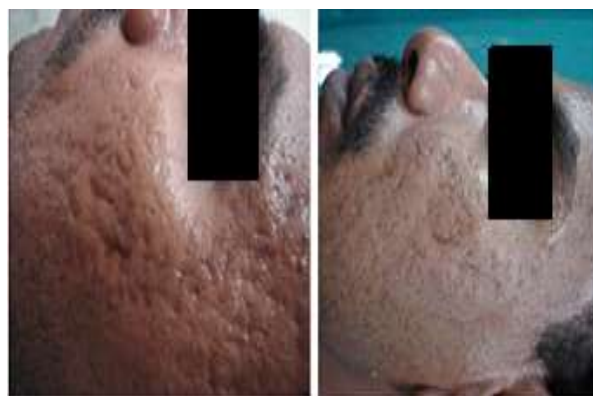

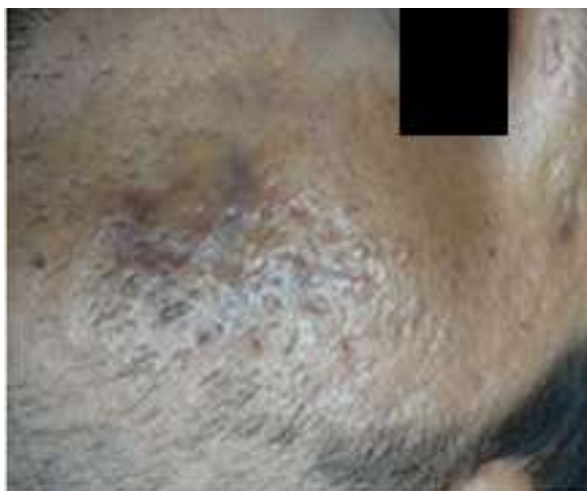Fig. 3a and 3b: Pre and Post Images of Dermabrasion (Grade 2)

The percentage Out of the 15 patients, 9 of them experienced erythema over the abraded area which persisted for about 2 weeks. Dressing removed after 3 to 5 days. Crusting took place in about 7 to 10 days. The results have been tabulated Table 3.

Table 3: Quartile grading and DLQI scales of Dermabrasion

		Dermabrasion	
		N	%
Gender	Male	12	80.0
	Female	3	20.0
Types of scar	Rolling	7	46.7
	Boxcar	4	26.6
	Boxcar, Rolling	4	26.6
Quartile grading scale	Grade 0, (<25%)	3	20.0
	Grade 1, (26–49%)	7	46.7
	Grade 2, (50–74%)	3	20.0
	Grade 3, >75%	2	13.3
Dyschromia	Negative	8	60.0
	Positive	7	40.0
Erythema	Negative	9	60.0
	Positive	6	40.0
DLQI	Before	10.80	
	After	7.08	

Pigmentary changes were seen in almost all the patients. Pigmentary disturbances more commonly seen in dermabrasion, as noted by the p value which is significant (Fig. 4).

**Fig. 4: Pigmentary changes in dermabrasion**

Discussion

People with Acne scars may face physical, aesthetic, psychological, and social consequences that may be associated with substantial emotional and financial costs.

In our study we observed that both dermaroller and dermabrasion techniques produced improvement in acne scars in most of the patients. Since only those

patients who had more than 25% improvement were taken to have significant improvement, the percentage improvement of scars in group A who underwent microneedling was 93% and that in group B which underwent dermabrasion was 80%. The difference in percentage improvement of scars between the two groups was statistically insignificant. There are many reports available which have studied the effects of each of these techniques individually. The percentage improvement seen in group A, which underwent microneedling using dermaroller for 4 sessions which is 93%, is comparable to that of the study done by Imran et al.⁽⁶⁾ The downtime observed for erythema and edema to subside after the dermaroller procedure was 2-3 days which was similar to that of the study by Fabroccini et al.⁽⁷⁾ The lesser downtime was also reported as an advantage in the study by Fernandes and Signorini et al.⁽⁸⁾ in which they reported that the absence of epidermal damage when compared to dermabrasion.

In our study, we observed that many patients in both groups reported improvement in the firmness of the face giving a lifted appearance which was intact for months even after the completion of the study. This effect was also reported in other studies such as that by Imran et al and Aust et al. The firmness was probably due to continuous collagen deposition and elastin up to 6 months after the procedure which was confirmed histologically in the study done by Aust et al.⁽⁹⁾ This lifted appearance provided extra anti-aging effects in our patients. Microneedling can provide both acne scar remodeling and anti-aging benefits in same sitting.

We observed that among the different types of scars box scars and rolling scars responded well to microneedling therapy. In our study there was post inflammatory hyperpigmentation observed among 40% of patients who underwent dermabrasion. This could have been because of the of dark skin type.

Microneedling: Microneedling provides collagen induction through controlled mechanical stimulation of the dermis resulting in softening of scars leading to realignment of old collagen bundles. There is complete preservation of the epidermis during the procedure.⁽¹⁰⁾ There is significant improvement in the DQLI score in microneedling which is reduced to a mean of 5 from a score of 10 in group A, Improvement of quartile grading scale was also noted in about 70 to 80% as graphically represented below (Fig. 5)

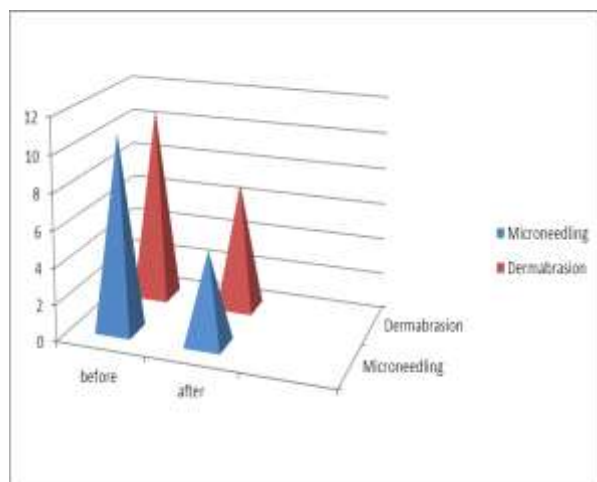


Fig. 5: Graphical representation of DLQI differences between Microneedling and Dermabrasion

In a study from Srinagar⁽¹¹⁾ which showed excellent response in about 70 to 80% for atrophic acne scars with microneedling therapy which correlated with our study. In a study conducted in Maharashtra.⁽¹²⁾ Microneedling alone or when combined with other modalities showed a significant degree of improvement about 70 to 80% improvements in rolling scars. Complication was not that much with microneedling only erythema was seen in about 73% that too subsided in about 2 to 3 days. Pigmentary changes were seen in about 40% which also subsided in about 3 weeks.

Dermabrasion consists of sequential planning of the depressed scars with electrical and/ or manual abraders and allowing the wound to heal by secondary intention, so as to achieve a levelling effect to make the scar less conspicuous.

In our study the success rate of dermabrasion was about 83%. Rolling and boxcar type of scars responded well. There is also a reduction in the DLQI score from a mean of 10 to about 7.

In a study by SS Savant⁽¹³⁾ using dermabrasion for acne scars success rate was comparable to our study. Regarding the complications Pigmentary disturbances seen in almost half of the patients and erythema was seen in about 66%.

There is no comparative studies published till date between effectiveness of microneedling and dermabrasion in post acne scars Only individual studies are available the results of these studies correlated with our study.

References

1. Rooks textbook of dermatology eighth edition page no 42.17.
2. Koo J. The psychosocial impact of acne: patients' perceptions. *J Am Acad Dermatol.* 1995;32:26-30.
3. Goodman G. Dermabrasion using tumescent anaesthesia. *Journal of Dermatological Surgery and Oncology:* 1994;20:802-7.

4. Orentreich N, Orentreich DS. Dermabrasion. *Dermatology Clinics* 1995;13:313-27.
5. Goodman G. Dermabrasion using tumescent anesthesia. *Journal of Dermatological Surgery and Oncology:* 1994; 20: 802-7.
6. Imran I. Microneedling therapy in atrophic facial scars: an objective assessment. *J Cutan Aesthet Surg.* 2009;2:26-30.
7. Fabbrocini G, Fardella N, Monfrecola A, Proietti I, Innocenzi D. Acne scarring treatment using skin needling. *British association of dermatology. Clin Exp Dermatol.* 2009;34:874-83.
8. Fernandes D. Minimally invasive percutaneous collagen induction. *Oral Maxillofac Surg Clin North Am.* 2006;17:51-63.
9. Aust MC, Fernandes D, Kolokythas P, Kaplan HM, Vogt PM. Percutaneous collagen induction therapy: an alternative treatment for scars, wrinkles, and skin laxity. *Plast Reconstr Surg.* 2008;121:1421-30.
10. Haider I, Pettis RJ, Davison N et al. Biomedical and fluid flow characterization of microneedle- based drug delivery devices. In: *Proceedings of the 25th Annual Meetings of the American Society of Biomechanics, San Diego, CA, August 2001.*
11. Majid I. Microneedling therapy in atrophic facial scars: An objective assessment. *Journal of Cutaneous Aesthetic Surgery* 2009; 2:26-30.
12. Sharad, J. (2011), Combination of microneedling and glycolic acid peels for the treatment of acne scars in dark skin. *Journal of Cosmetic Dermatology,*10:317-323.
13. Savant SS. Facial dermabrasion in acne scars and genodermatoses-A study of 65 patients. *Indian Journal of Dermatology Venereology and Leprology* 2000;66:79-84.
14. Lee JW et al. Treatment of acne scars using subdermal minimal surgery technology. *Dermatological Surgeries* 2010 Aug; 36:1281.