

Analysis of dermatological manifestations of dengue fever

Bela B. Padhiar^{1,*}, Dhvani Makwana²

¹Associate Professor & HOD, ²Resident, Dept. of Dermatology, GMERS Medical College, Gandhinagar, Gujarat

***Corresponding Author:**

Email: drbelapadhiar@gmail.com

Abstract

Introduction: Dengue fever and related infections are increasing especially in tropical countries like India. Dengue fever may present with the dermatological manifestations but enough data is not available focusing them. This study was conducted to investigate dermatological manifestations of dengue fever (DF).

Materials and Method: Prospective study was conducted for period of 3 months (August – October 2016) in a tertiary care hospital. All the indoor patients with febrile illness and suspected to have dengue fever were screened and only serologically positive for Dengue Fever cases were included in the study and analyzed for age, gender and mucocutaneous features - its treatment and outcome.

Results: Out of 326 suspected dengue cases, 104 serologically confirmed for DF. Out of these 104 patients, 71.15% were male and 28.85% were female. Age of patients ranged from 8 – 62 years. 55 (52.88%) patients had cutaneous manifestations and 15 (14.42%) had additional mucosal involvement. Out of these 55 patients, 58.1% had maculopapular rash, 21.9% had ecchymotic manifestations, 14.6% cases had patchial manifestations. Pruritus was present in 36.3% cases. Out of 55 cases, 50.9% had generalized distribution of rash while 29.1% and 20% had trunk and limb involvement respectively. Out of 15 patients with mucosal manifestations, 11(73.33%) had conjunctival congestion, 3(20%) had lip crusting and only 1(6.7%) patient had soft palate vesicle.

Conclusion: Dermatological manifestations are common presenting features of dengue fever patients but not present in all patients. Identification of them helps us in early diagnosis and better management of patients.

Introduction

Dengue virus infection, a mosquito-borne disease, has spread rapidly in last 50 years.⁽¹⁾ It is the most common and widespread arthropod borne viral infection in the world today.⁽²⁾

Dengue fever (DF) caused by four distinct types of single stranded RNA dengue virus, affect infants, young children, and adult MANIFESTED mainly in 3 forms DF, dengue hemorrhagic fever (DHF), dengue shock syndrome (DSS).⁽³⁾

Dengue fever is characterized by high grade fever, myalgia, arthralgia, headache, retrobulbar pain and skin rash.⁽³⁾

Various type of cutaneous lesions occur in dengue virus infection such as transient erythema with facial flushing withing first 24-48 hour, maculopapular rash or mobiliform rash, ecchymotic and patchial lesion, generalised rash with “islands of white in a sea of red” and mucosal lesion which are conjunctival congetion, lips crusting, and soft palate vesicle.

Aim and Objective

To study various dermatological manifestations in case of dengue fever.

Materials and Method

This prospective study was conducted for period of 3 months (August – October 2016) in a medical ward, GMERS Medical College, Tertiary Care Hospital, Gandhinagar.

All the indoor patients with febrile illness and suspected to have dengue fever were screened. Only

serologically positive (ELISA IG M and NS1 antigen test) for dengue fever cases were enrolled in the study.

An informed consent was obtained. A detailed history taking and Clinical examination to assess the various cutaneous features was carried out and relevant investigations were done.

The data was entered in case record form and analysed.

Results

Out of 326 suspected dengue cases, 104 serologically confirmed for DF were enrolled in our study. Among these 104 confirmed cases of DF 74(71%) were male and 30(29%) were female. The male: female ratio was 2.5:1.

Age ranges from 8 – 62 years with most of the patients belong to 21 to 40 years of the age group. (Table 1)

Out of 104 serologically confirmed cases, 55 patients had mucocutaneous manifestation, among which maculopapular rash being common 58.1% (Table 2).

Involvement of various body area by dengue rash was generalized in 28cases (50.9%) followed by trunk and limb involvement was 16 cases (29.1%) and 11 cases (20%) respectively (Table 3).

In study out of 55 cases of mucocutaneous manifestation, 20 cases had pruritus with rash (Table 4).

Gender Distribution Chart

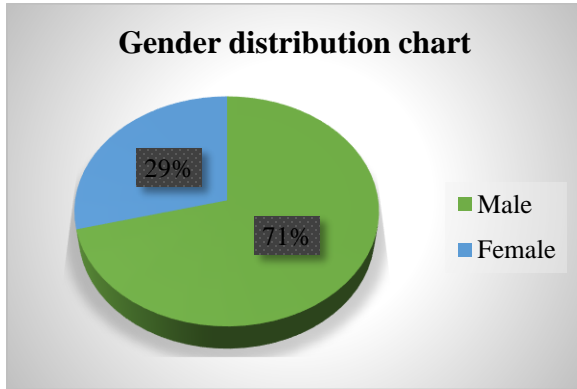


Table 1: Age and gender distribution of patients

Age (years)	Male	Female	Total	Percentage
<10	03	01	04	3.8%
11-20	15	04	19	18.3%
21-30	12	05	17	16.3%
31-40	18	09	27	26.0%
41-50	16	06	22	21.1%
51-60	06	03	09	8.7%
61-70	04	02	06	5.8%

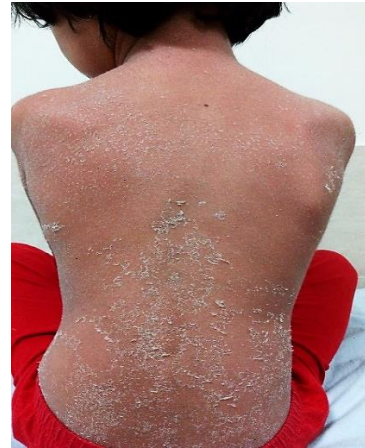

Fig. 2

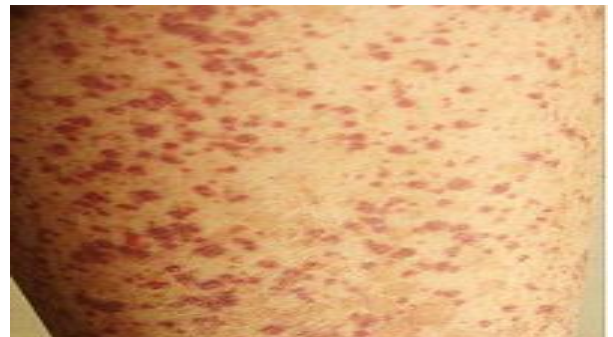


Fig. 3

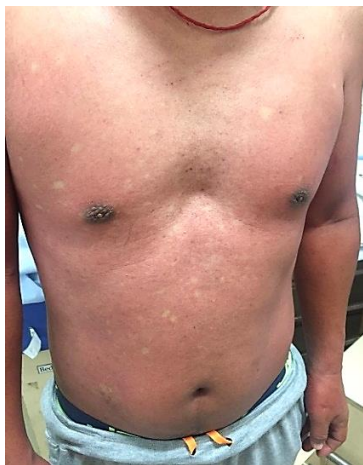

Fig. 1

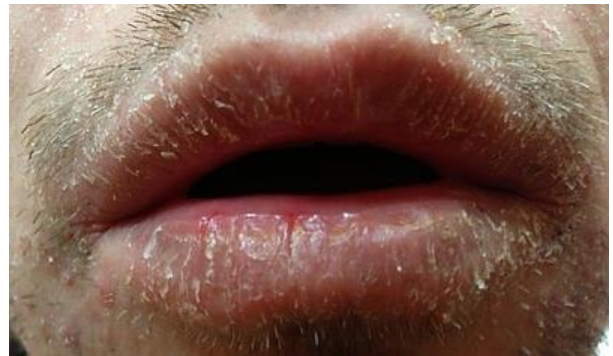

Fig. 4

Morphological patterns of various mucocutaneous manifestation in patients with dengue fever (n=55).

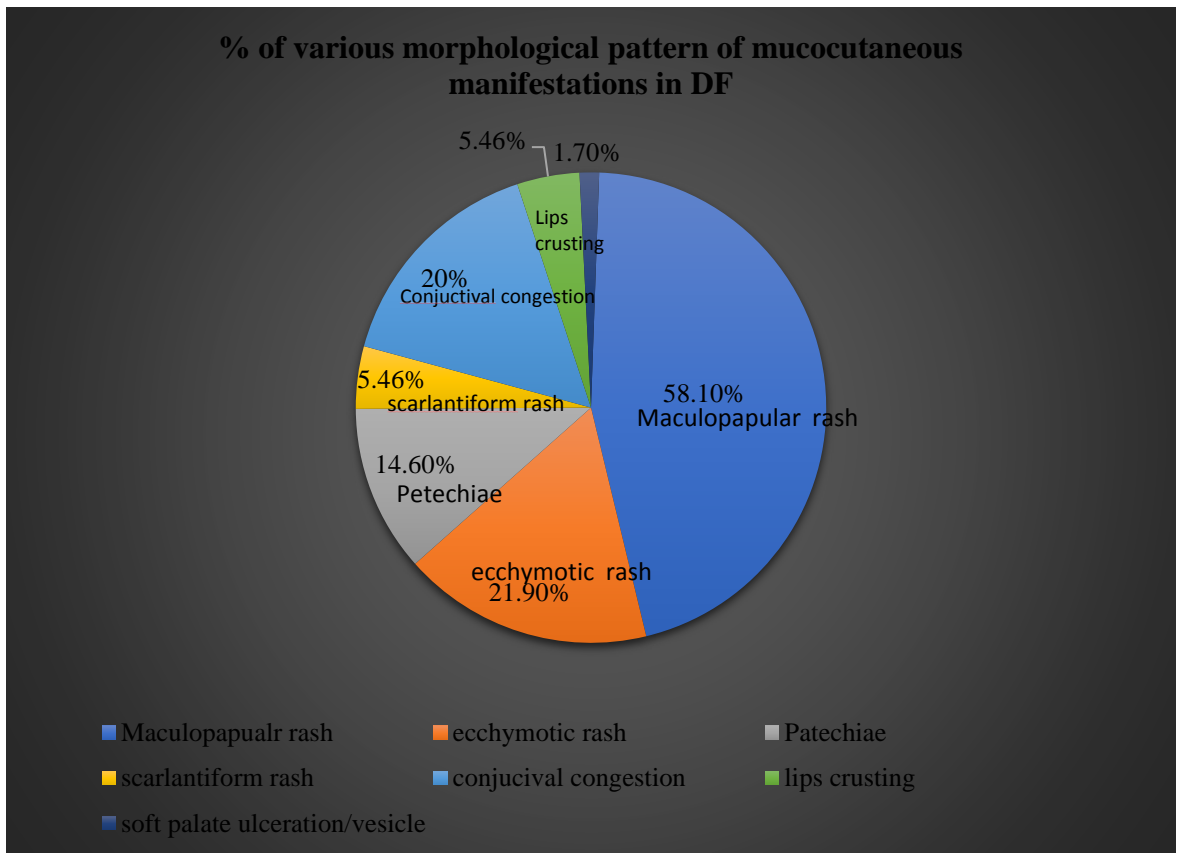
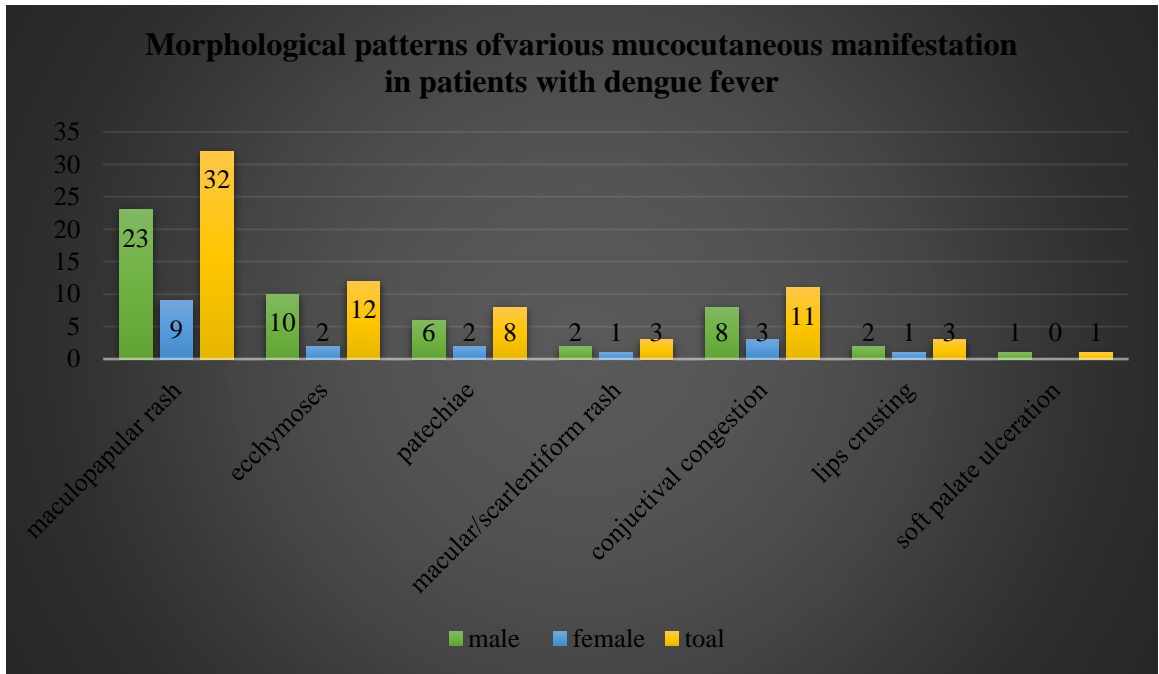


Table 2: Dermatological involvement in patients with dengue fever

Dermatological involvement	Male	Female	Total	Percentage
Mucocutaneous	11	4	15	14.42%
Only cutaneous	30	10	40	38.46%
No dermatological involvement	33	16	49	47.12%

Table 3: Distribution of rash in patients of dengue fever

Distribution of rash	Male	Female	Total	Percentage
Generalized	18	10	28	50.9%
Truncal	13	3	16	29.1%
Extremities	10	1	11	20%

Table 4: Dengue rash with / without pruritus in patients of dengue fever

Dengue Rash	No. of cases	Percentage
Without Pruritus	35	63.7%
With pruritus	20	36.3%

Discussion

Dengue fever is a rapidly growing public health problem especially tropical and subtropical countries.⁽³⁾

The past 6 decades have witnessed a worrisome rise in epidemic as well as increase in disease severity.⁽⁴⁾ It might be due to changing climate, urbanisation, poor living condition, and inadequate waste disposal.

In present study out of 104 cases, 74(71.15%) were male and 30(28.85%) were female, with male:female ratio of 2.5:1. This type of male preponderance is also reported in other studies carried out by kumar et al, Khan E et al.^(5,6) Anker M et al, & Shekhar KC et al.^(7,8)

Dengue fever is a rapidly growing public health problem especially tropical and subtropical countries.⁽³⁾

The past 6 decades have witnessed a worrisome rise in epidemic as well as increase in disease severity.⁽⁴⁾ It might be due to changing climate,

urbanisation, poor living condition, and inadequate waste disposal.

In present study out of 104 cases, 74(71.15%) were male and 30(28.85%) were female, with male:female ratio of 2.5:1. This type of male preponderance is also reported in other studies carried out by kumar et al, Khan E et al,^(5,6) Anker M et al, & Shekhar KC et al.^(7,8)

Dengue fever is a rapidly growing public health problem especially tropical and subtropical countries.⁽³⁾

The past 6 decades have witnessed a worrisome rise in epidemic as well as increase in disease severity.⁽⁴⁾ It might be due to changing climate, urbanisation, poor living condition, and inadequate waste disposal.

In present study out of 104 cases, 74(71.15%) were male and 30(28.85%) were female, with male:female ratio of 2.5:1. This type of male preponderance is also reported in other studies carried out by kumar et al, Khan E et al,^(5,6) Anker M et al, & Shekhar KC et al.^(7,8)

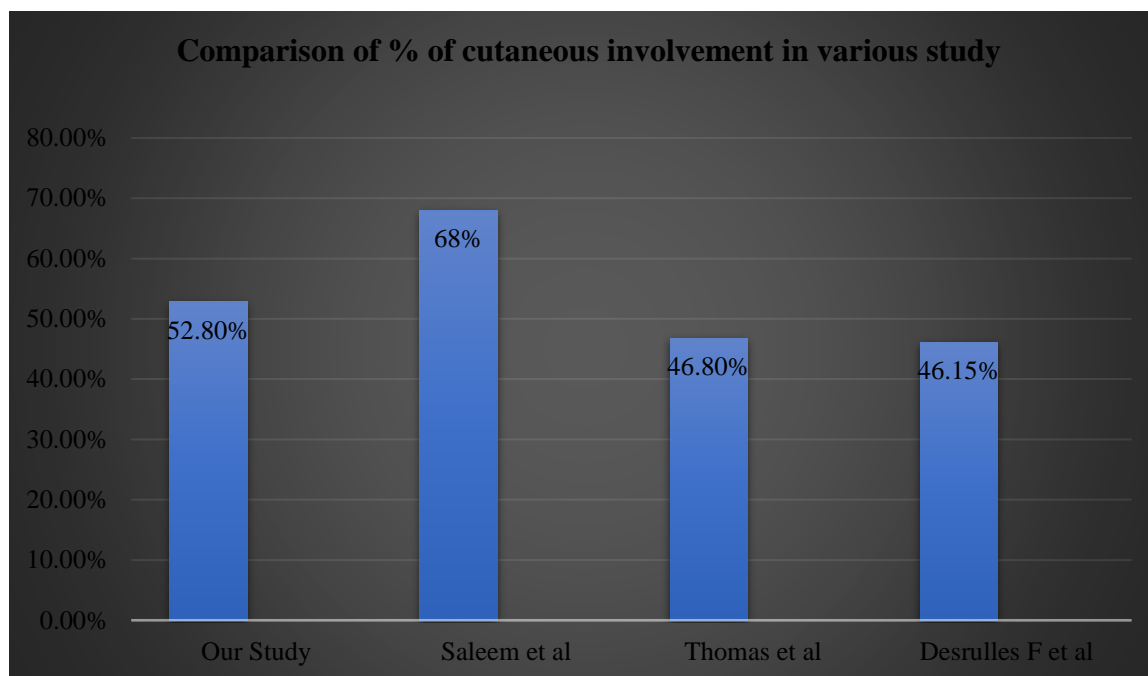
In our study 36.3% cases had pruritus with rash, whereas 63.7% had asymptomatic rash. Similarly study by Thomas et al shows that 27.6% patients had pruritic rash.⁽⁴⁾

Generalized Involvement was in 50.9% of patients, trunk and limb involvement in 29.1% & 20% respectively; Similarly in Thomas et al study, generalized involvement in 48.3% cases, and limb and trunk involvement was 18.9% and 32.8% respectively.⁽⁴⁾

Usually mucosal involvement is seen 15-30% cases of DF,⁽³⁾ which includes conjunctival congestion, crusting of lips, small vesicle or ulceration on soft palate, crusting or drying of tongue.⁽³⁾

In our study, mucosal involvement was seen in 27.3% of patients, with conjunctival congestion being most common in 20%, followed by lips crusting in 5.4% and soft palate ulceration in 1.9% patients.

In study by Thomas et al, mucosal involvement was 29.8% of patients, with involvement of conjunctiva, lips, palate and tongue was 20.9%, 4.8%, 2.4% and 1.6% respectively.⁽⁴⁾



Conclusion

This study highlights muco-cutaneous manifestation seen in dengue fever and related complications.

Dermatological manifestations are common presenting features of dengue fever patients but not present in all patients. Identification of them helps us in early diagnosis and better management of patients.

References

1. Khan E, Hasan R. dengue infection in Asia; A Regional concern, Editorial. *J Post Graduate Med Inst* 2012;20(1);1-6.
2. World Health Organization, Scientific Working group on dengue meeting report, Geneva, Switzerland. Geneva: WHO;2000
3. K.A. Seetharam, IADVL Textbook of Dermatology, fourth edition 2015, vol-1; 612-614.
4. Thomas EA, John M, Kanish B. Mucocutaneous manifestation of dengue fever. *Indian J Dermatol.* 2010;55:79-85.
5. Kumar A, Rao CR, Pandit V, Shetty S, Bammigatti C, Samarasinghe CM. Clinical manifestation and trend of dengue cases admitted in tertiary care hospital, udupi district, Karnataka. *Indian J Community Med* 2010;35(3);386-90.
6. Khan E, Khan N, Kismat E, Nasir A, Ayub S, Hasan R. Demographic and clinical feature of dengue fever in Pakistan from 2003-2007: a retrospective cross sectional study *plos one* 2010;58(9);e12505.
7. Anker M, Arimab Y. Male female difference in dengue incidence in Asia. *Western Pak Surveill Response J.* 2011;2;17-23.
8. Shekhar KC, Haut OL. Epidemiology of dengue / dengue hemorrhagic fever in Malaysia- a retrospective epidemiological study 1973-1987. *Asia Pac J Public He* 1992-93;6;15-25.

9. Saleem K, Sheikh I. Skin lesion in hospitalized case of dengue fever. *J Coll Physicians Surg Pak.* 2008;18:608-11.
10. Desruelles f, Lamury I, Ronidier M, Goursand R, Mahe A, Castanet J, et al. Cutaneous manifestation of dengue. *Ann Dermatol Venerol* 1997;124(3);237-41.