

Efficacy and safety of platelet rich plasma (PRP) as monotherapy in the management of acne scars in a tertiary care centre

Afthab Jameela Wahab¹, Anandan V.², Mani Surya Kumar M.^{3,*}, Shubhra Shukla⁴

¹Professor, ²Professor & HOD, ³Assistant Professor, ⁴Junior Resident, Dept. of Dermatology, Govt. Stanley Medical College, Chennai, Tamil Nadu

***Corresponding Author:**

Email: mkmanisurya@gmail.com

Abstract

Introduction: Acne vulgaris can lead to lifelong sequelae in the form of atrophic or hypertrophic scars, depending on the degree of inflammation. Acne scar management remains a challenge to dermatologists. Platelet rich plasma (PRP), in which the platelets are in a highly concentrated form, has shown its effect in accelerating tissue repair and wound healing. The platelets release a variety of growth factors which bring about tissue remodelling.

Aim: To study the efficacy and safety of PRP in treating acne scars at a tertiary care centre in South India.

Materials and Method: Based on inclusion and exclusion criteria forty patients were included in the study. PRP was prepared by double spin method. The area to be treated was cleaned with spirit, the skin was stretched and activated PRP loaded in an insulin syringe was injected into and around the scars through multiple punctures. The procedure was repeated every 4 weeks for 6 months.

Results: Out of 40 patients, 42.5% patients (17) showed marked improvement in the grading of acne scars i.e., they improved up to grade 1 or there was an improvement by 2 grades. 35% patients (14) showed moderate improvement i.e., grading of acne scar improved by 1. In 15% (6) patients, although the grading did not change, there was visible improvement in the appearance of the scars. In 7.5% patients (3), there was no improvement even after 6 sittings of PRP, probably requiring combination with other treatment modalities.

Conclusion: Platelet rich plasma therapy is easy to perform. Done as an outpatient procedure, it does not hamper the daily activities of the patient. It works well for superficial acne scars, providing good results with minimal side effects like erythema and edema that subside within 2-6 hours. PRP is thus an effective modality for treating acne scars.

Keyword: Acne Scars, Platelet Rich Plasma (PRP), Monotherapy

Introduction

Acne is a disease of the pilosebaceous unit commonly affecting adolescents. Clinically characterized by pleomorphic lesions, in most cases it is self-limiting. However, it is often associated with scarring, varying from minimal to severe,⁽²⁾ depending on the degree of inflammation occurring during the disease process.⁽¹⁾ The scars, either atrophic or hypertrophic, occur due to defective tissue healing. Acne scars are of the following types – ice-pick scars, rolling scars, boxcar scars, perifollicular elastolysis, perifollicular fibrosis, hypertrophic scars or atrophic macules.⁽³⁾ Management usually involves a combination of treatment modalities as a single approach may not produce desired results. Various methods in use for acne scar management include topical agents like tretinoin or steroids, punch elevation, punch grafting, subcision, microdermabrasion, dermabrasion, lasers and fillers. Of late, the use of autologous Platelet Rich Plasma (PRP) for acne scars is gaining popularity. Platelets extracted from one's own blood are re-injected in a highly concentrated form into the area where their effect is desired, to carry out their function in a more directed way. The platelets release a variety of growth factors with the potential to bring about tissue remodelling by regulating cell migration, proliferation, differentiation and extra cellular matrix accumulation.⁽⁵⁾

PRP is effective in accelerating tissue repair & wound healing.⁽⁴⁾ It therefore holds a place in the treatment of acne scars when used either alone or in combination with other methods.

Aim and Objective of the study

To assess the efficacy and safety of platelet rich plasma (PRP) for the treatment of acne scars.

Materials and Method

A prospective, non-randomised, interventional study was conducted at a tertiary care centre in South India from June 2013 to May 2014. A total of forty patients were included in the study after getting approval from the institutional ethical committee and informed written consent from the patients. Inclusion criteria was acne patients of both sexes, aged above 18 years with atrophic acne scars like rolling and boxcar scars and those willing for follow up and being photographed. Exclusion criteria included active nodulocystic acne, active skin infections, keloidal tendency, bleeding disorders, oral steroid or anticoagulant therapy, pregnancy, diseases like SLE, porphyrias, metabolic and systemic disorders and patients on oral isotretinoin for the past one month. A brief and relevant medical history and physical examination was done at a screening visit to ensure

relevant eligibility criteria. Patients were elaborately explained about the procedure; PRP therapy, its benefits, possible side effects, the prognosis was informed and informed written consent was obtained. All patients were subjected to routine blood and urine examination, serology for HIV, HBV and HCV. The patients were thoroughly evaluated. Digital photographs of the face were taken. Grading of acne scars was done.

Grading of Acne Scars

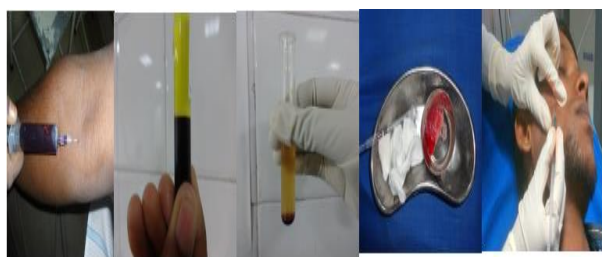
Macular: Erythematous, hyper- or hypopigmented flat marks. No problem of contour like other scar grades.

Mild: Mild atrophic scars that may not be obvious at social distances of ≥ 50 cm and may be covered adequately by makeup or the normal shadow of shaved beard hair in men.

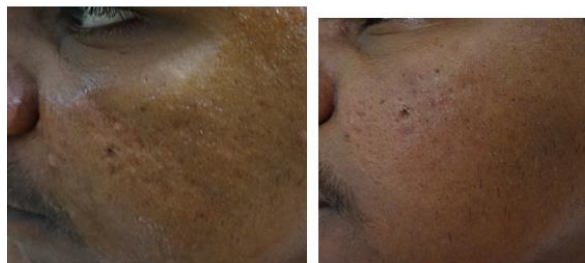Moderate: Moderate atrophic scarring that is obvious at social distances ≥ 50 cm and is not covered easily by makeup or the normal shadow of shaved beard hair in men, but is still able to be flattened by manual stretching of the skin.

Severe: Severe atrophic scarring that is evident at social distances >50 cm and is not covered easily by makeup or the normal shadow of shaved beard hair in men and is not able to be flattened by manual stretching of the skin.

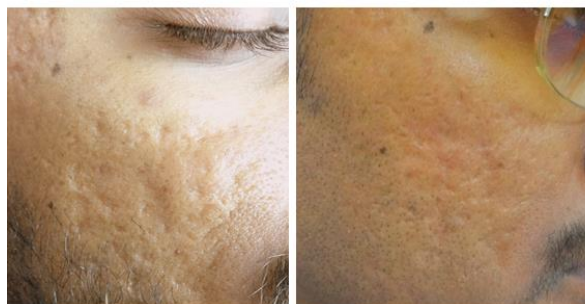PRP Preparation: The process was carried out under strict aseptic conditions. Room temperature was maintained at 22- 26⁰C. 10 ml of blood was collected from the patient in the centrifuge test tube (labelled with patient’s name and age) and mixed with anticoagulant Acid Citrate Dextrose (ACD)⁽⁶⁾ in the ratio of 10: 1.5. The tube was then placed for first centrifugation, soft spin at the rpm of 2000 for ten minutes. At the end of this, the separated plasma, buffy coat and uppermost layer of red blood cells were pipetted out into another tube. The uppermost layer of RBCs was collected because it has been shown to contain a portion of young platelets. This collected part was subjected to second centrifugation, a hard spin at the rpm of 3000 for another ten minutes. At the end of this step, platelets settled down at the bottom of the test tube. The upper three-fourth of supernatant was discarded without disturbing the lower layer, the lowest portion obtained being Platelet Rich Plasma. PRP now ready for use, was activated just before injection into the skin by adding to it 10% calcium chloride in the ratio of 1: 10 (1 part CaCl₂, 10 parts PRP) and agitating it by vigorous shaking (Fig. 1).



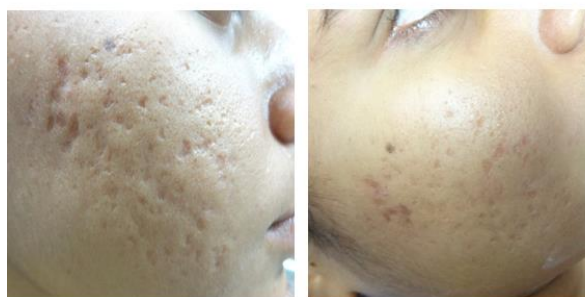PATIENT 1
BEFORE TREATMENT
AFTER 4 SITTINGS OF PRP TREATMENT
(MARKED IMPROVEMENT)



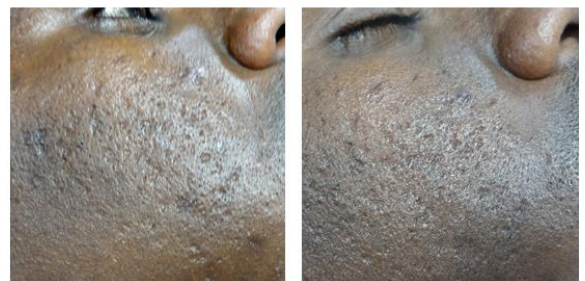PATIENT 2
BEFORE TREATMENT
AFTER 6 SITTINGS OF PRP TREATMENT
(MARKED IMPROVEMENT)



PATIENT 3
BEFORE TREATMENT
AFTER 6 SITTINGS OF PRP TREATMENT
(MARKED IMPROVEMENT)

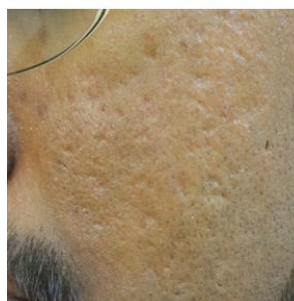

PATIENT 5
BEFORE TREATMENT
AFTER 6 SITTINGS OF PRP TREATMENT
(MILD IMPROVEMENT)

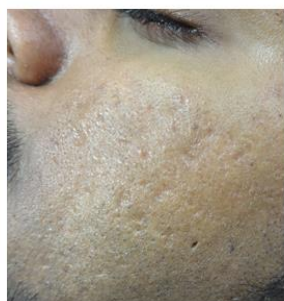

PATIENT 6

BEFORE TREATMENT



AFTER 6 SITTINGS OF PRP TREATMENT
(MODERATE IMPROVEMENT)



Procedure: The area to be treated was anaesthetized with topical anaesthesia like EMLA. After about 45 minutes, the area to be treated was cleaned with spirit. The skin was stretched and the activated PRP was loaded in insulin syringe and injected into the scars and around it through multiple punctures. Mild erythema was seen immediately after the procedure. The face was wiped with a mild cleanser.

Post procedure advice and follow up: Patients were advised not to vigorously rub the face for 12 hours and not to take aspirin or other anti inflammatory drugs while on therapy. No dressing was required. The same procedure was carried at intervals of 4 weeks for 6 months. At every visit, clinical photographs were taken, patient satisfaction was assessed and scored and clinical grading was done, according to the following scale.

Score	Patient's Satisfaction	Improvement in Acne Scars%	Improvement in Acne Scars Grade
0	Not at all satisfied	0-25%	Minimal
1	Not satisfied	25- 50 %	Mild
2	Partially satisfied	50-75 %	Moderate
3	Satisfied	>75%	Near Total
4	Highly satisfied		

Observation and Results

This study included 40 patients, 30 males and 10 females. The youngest age was 18 years and the oldest 31 years. Twenty were in the 20-25, sixteen in the 25-30, two each in the 18-20 and over 30 age groups. Most were in the 20-30 age group.

Eighteen patients had rolling scars, fourteen had both rolling and boxcar scars and eight had boxcar scars.

After PRP therapy, out of 40 patients, 42.5% patients⁽¹⁷⁾ showed marked improvement in the grading of acne scars, that is, they improved upto grade 1 or there was an improvement by 2 grades. 35% patients⁽¹⁴⁾ showed moderate improvement. In these patients grading of acne scar improved by 1. In 15%⁽⁶⁾ patients although the grading did not change, there was visible

improvement in the appearance of the scars. In only 7.5% patients,⁽³⁾ there was no improvement seen even after 6 sittings of PRP, who were probably candidates for combination with other modalities (Fig. 2).

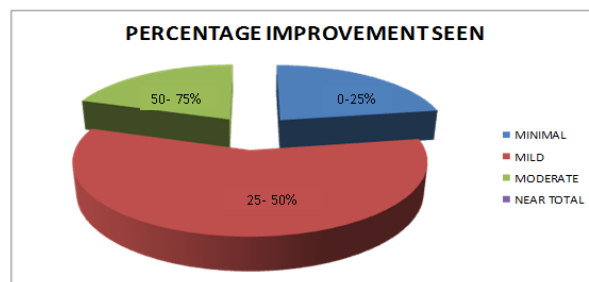


Fig. 2: Percentage improvement in acne scars

After 3 sittings of the procedure, appreciable changes were seen on the skin surface of the patients. Mild improvement was seen in 23, moderate improvement in 8 and minimal improvement in 9 patients. After 6 sittings, there was around 40 % improvement in the appearance of the skin with PRP therapy alone. This was seen both objectively as well as subjectively (Table 1).

Table 1: Improvement in acne scars

Improvement in Acne Scars	No. of Patients
0-25% (Minimal)	9
25- 50 % (Mild)	23
50-75 % (Moderate)	8
>75% (Near Total)	0

Among the patients who showed improvement, 57.5% patients showed this improvement after the third sitting. In 15%, improvement was first seen at the fourth sitting. In a small group of patients (5%), the effect could be appreciated at the end of second sitting itself.

Eleven patients were satisfied and 27 patients were partly satisfied with the procedure outcome (Table 2). Around 52.5% patients put their satisfaction score as 'good' at the end of procedure, while 27.5 % patients scored it as 'very good'. 12.5% patients gave a score of 'fair'. Only 7.5% gave a 'poor' score (Fig. 3). The mean DLQI of the patients changed from 22.9 before treatment to 8.9 after treatment (61.13% improvement).

Table 2: Patient satisfaction score

Patient's Satisfaction Score	No. of Patients
Not at all satisfied – 0	0
Not satisfied- 1	2
Partially satisfied -2	27
Satisfied- 3	11
Highly satisfied- 4	0

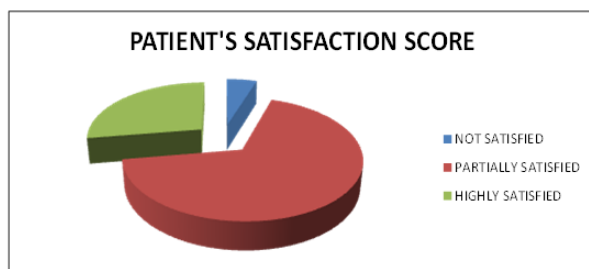


Fig. 3: Patient satisfaction score

The major complication was immediate post-procedure erythema, seen in all 40 patients. The erythema however was transient and resolved in 6- 12 hours. Even after proper application of topical numbing cream, around 5 patients complained of mild discomfort during the procedure. Apart from these, no other complication was seen. A follow-up period upto 6 months showed that the results were permanent and there were no complications.

Discussion

Scarring in acne is due to abnormal healing following the damage caused by the accompanying inflammatory process. These inflammatory events are brought about by cell-mediated immune response. Scarring is determined by the severity of inflammation as measured by depth and duration. Patients with moderate to severe acne scars experience anxiety, shame, lack of self confidence, embarrassment, stress and impaired social contact. They may face problems of unemployment. There have been reports of acne patients committing suicide.⁽⁷⁾ Prevention is better than cure. So treatment of acne should be begun as early as possible to prevent formation of acne scars. Various procedures used for acne scars are chemical peels, CROSS (chemical reconstruction of skin scars), subcision, dermabrasion, microdermabrasion, laser resurfacing, punch elevation and excision, skin needling, Platelet rich plasma PRP, fillers and scar excision.

PRP has been used therapeutically to accelerate wound healing and tissue repair in dentistry since 1998. The clinical application of PRP has recently expanded to other fields, including cardiac surgery, ophthalmology, oral and maxillofacial surgery, orthopaedic surgery, plastic surgery, sports medicine, and cosmetic medicine.⁽⁸⁾ PRP, a novel approach to treatment of acne scars, utilises one's own platelets to heal the scars. It causes regeneration, rejuvenation and stimulates wound healing. It is believed to induce local tissue re-modelling and angiogenesis by activating tissue-resident progenitor /stem cells; it may also recruit bone-marrow-derived progenitor/ stem cells. This technology allows platelets and white blood cells from the patient's blood to be concentrated and, by injecting the solution directly into the injured tissue to induce the release of growth factors, thereby stimulates the same

healing process but in a more directed form. It utilises the body's ability to heal itself. PRP is superior to other methods for acne treatment as it is safer and comparatively cost effective, with no chance of further scarring or damage. It is relatively painless when done after applying a numbing cream.

Most of the studies available have combined platelet rich plasma with conventional treatment for acne scars. Studies have shown the effectiveness of PRP when used in conjunction with other modalities like lasers or dermabrasion. However, the individual effect of PRP as monotherapy for acne scars has not been studied extensively. But there is a paucity of studies showing the role of platelet rich plasma as monotherapy in acne scars. The purpose of this study was to see the individual role of platelet rich plasma in the treatment of acne scars.

In a study done by Jiang Ting Zhu et al combining Erbium fractional laser with PRP, 90.9% of the patients showed an improvement of over 50%, and 91% of the patients were satisfied.⁽⁹⁾ However this study could not precisely tell about the role of PRP alone in remodelling of tissues.

Lee et al conducted a split-face trial that treated acne scars with PRP following ablative CO2 fractional resurfacing.⁽¹⁰⁾ Fourteen Korean participants with acne scars were included in this study. They received one session of ablative CO2 fractional resurfacing, and then facial halves were randomly assigned to receive treatment with autologous PRP injections on one side (experimental side) and normal saline injections on the other side (control side). Erythema and edema on the experimental side improved faster than on the control side, and overall, degree of clinical improvement was significantly better on the experimental side than on the control side.

Another study done by Alessio Redaelli et al on face & neck revitalization using PRP alone showed that PRP is an easy to perform and promising technique in face & neck revitalization & scar attenuation.⁽¹¹⁾ Patients were treated with 3 sessions of PRP injections alone at intervals of 4 weeks. A photograph score, patient's satisfaction score and doctor's satisfaction score all together showed an overall satisfactory result.

In a study combining use of skin needling and platelet-rich plasma in acne scarring treatment by Gabriella Fabbrocini et al, it was shown that the combined the use of skin needling and PRP is more effective in improving acne scars than skin needling alone.⁽¹²⁾ The study showed that the micro-needling apart from inducing new collagen synthesis made the PRP penetration easier, which helped in the action of the growth factors present in the PRP.

In our study, instead of using micro-needling technique, PRP was directly injected into acne scars. In our study, after PRP therapy, out of 40 patients, 42.5% patients⁽¹⁷⁾ showed marked improvement in the grading of acne scars, 35% patients⁽¹⁴⁾ showed moderate

improvement and in 15%⁽⁶⁾ patients, there was visible improvement in the appearance of the scars. After 6 sittings, there was around 40% improvement in the appearance of the skin with PRP therapy alone seen both subjectively and objectively. The mean DLQI of the patients changed from 22.9 before treatment to 8.9 after treatment (61.13% improvement).

Bouwer et al also studied the effects of PRP mesotherapy in skin rejuvenation and scar attenuation.⁽¹³⁾ They reported a very high (60%) improvement in post-acne scars with two sittings of PRP alone, results being visible at around 6 weeks after the procedure.

PRP is a novel approach in the management of atrophic acne scars. The result is comparable with other approaches for acne scars when used singly. Procedures like dermabrasion and ablative lasers have produced similar results. However they always carry the risk of pigmentation and scarring.

Limitation

Our study has not compared PRP with other traditional methods used to treat acne scars. Patients were followed up for only 6 months.

Conclusion

Platelet Rich Plasma therapy is easy to perform, and provides good results with minimum side effects. Platelet rich plasma therapy works well for superficial type of scars and does not hamper daily activity of the patient as it is performed as an outpatient procedure. Minimal side effects like erythema and edema which subside in 2-6 hours. Thus we may include PRP in the armamentarium for treating superficial acne scars, even as a monotherapy.

References

1. Rook's Textbook of Dermatology, 8th edition. Edited by DA Burns, SM Breathnach, NH Cox and CEM Griffiths. 2010 Blackwell Publishing Ltd. Cole GT.
2. Holland DB, Jeremy AH, Roberts SG et al. Inflammation in acne scarring: a comparison of the responses in lesions from patients prone and not prone to scar. *Br J Dermatol* 2004;150:72-81.
3. Jacob CI, Dover JS, Kaminer MS. Acne scarring: A classification system and review of treatment options. *J Am Acad Dermatol* 2001;45:109-17.
4. Marx RE, Garg AK. Dental and Craniofacial Applications of Platelet-Rich Plasma. Chicago: Quintessence Publishing; 2005.
5. Steed DL. The role of growth factors in wound healing. *Surg Clin North Am* 1997;77:575-86.
6. Robert E. Marx, DDS. Platelet Rich Plasma .What is PRP and What Is Not PRP? *Implant Dentistry* Vol. 10 No. 4 2001.
7. Cotterill JA, Cunliffe WJ. Suicide in dermatological patients. *Br J Dermatol* 1997;137:246-50.
8. Bhanot S, Alex JC. Current applications of platelet gels in facial plastic surgery. *Facial Plast Surg* 2002;18:27-33.
9. Jin-HuiCai, Gui-Qiu Shan, Jiang-Ting Zhu, Min Xuan, Hong- Wei Liu, Yan-Hong Wu, Xiao-Fei Xiang, Ya-Ni

- Zhang, and Biao Cheng, "The efficacy of autologous platelet-rich plasma combined with erbium fractional laser therapy for facial acne scars or acne," *Molecular Medicine Reports*, vol. 8, no. 1, pp.233–237, 2013.
10. Lee JW, Kim BJ, Kim MN, Mun SK. The efficacy of autologous platelet rich plasma combined with ablative carbon dioxide fractional resurfacing for acne scars: A simultaneous split-face trial. *Dermatol Surg* 2011;37:931-8.
11. Redaelli A, Romano D, Marcianó A. Face and neck revitalization with platelet-rich plasma (PRP): Clinical outcome in a series of 23 consecutively treated patients. *J Drugs Dermatol* 2010;9:466-72.
12. Gabriella Fabbrocini, MD et al. Combined Use of Skin Needling and Platelet-Rich Plasma in Acne Scarring Treatment. VOL. 24 No. 4 April 2011. *Cosmetic Dermatology*.
13. Bouwer W, Laurens I, Snyman JR. The in vitro properties of and in vivo results obtained via series of case studies demonstrating effect of platelet rich plasma (PRP) extracted and activated with the cellu Vance™ PRP kit improvement of different aesthetic and injury related cases.