

## Oral mucosal lesions in geriatric population- South Indian hospital based study

Jameema Corneli Peter<sup>1,\*</sup>, Rajashekar T.S<sup>2</sup>, S.M. Azeem Mohiyuddin<sup>3</sup>, Suresh Kumar Kuppaswamy<sup>4</sup>

<sup>1</sup>Junior Resident, <sup>2,3</sup>Professor & HOD, <sup>4</sup>Assistant Professor, <sup>1,2,4</sup>Dept. of Dermatology, <sup>3</sup>Dept. of Otolaryngology, Sri Devaraj Urs Medical College, Tamaka, Kolar, Karnataka, India

**\*Corresponding Author:**

Email: jameemacorneli@gmail.com

### Abstract

**Introduction:** Oral health is important to individuals of all age groups. The oral mucosa performs essential protective functions that plays an important role in the general health status of an individual. As a result of aging, oral epithelium undergo atrophic changes leading to decrease in tissue regeneration and disease resistance, which can expose the oral mucosa to a variety of pathogens and chemicals. In present study, we aimed to document the clinical types of oral mucosal lesions and to study its distribution and possible etiological factors in geriatric population.

**Materials and Methods:** A total number of 5257 patients above 60 years of age were examined and 130 patients fulfilling the criteria were enrolled for the study. A written consent taken from the patients. A detailed medical history and general physical examination was done to establish the clinical diagnosis. Correlation, if any, with etiological factor was assessed. In relevant cases, necessary investigations to establish the definitive diagnosis were done. The collected data were analyzed by the SPSS 22 version software.

**Results:** In the present study, age group of 60-69 years were commonly involved, with a male preponderance. Buccal mucosa was the most common site involved. The common risk factors observed were smoking, alcohol and betel quid chewing. The most frequent lesions found were malignancy, oral candidiasis and oral lichen planus followed by premalignant etiologies.

**Conclusion:** This present study brings to light various oral mucosal lesions in geriatric population, which also highlights the importance of early diagnosis of oral precancerous lesions before it develops into malignancy.

**Keywords:** Oral mucosal lesions, Geriatrics, Oral carcinoma, Premalignant lesions, Betel quid.

### Introduction

Oral health is important to all individuals as the oral mucosa performs essential protective functions that plays an important role in the general health status of an individual.<sup>1</sup> As per WHO definition, a population aging more than 60 years old should be considered to be an elderly population.<sup>2</sup>

In the aging individual, the systemic comorbidities and concurrent medications can cause decline in the protective function which could expose the oral mucosa to a variety of pathogens and chemicals. Aging can cause atrophic changes like thinning of oral epithelium and reduction in collagen synthesis which leads to impaired tissue regeneration and disease resistance.<sup>2</sup>

Various oral carcinogens including smoking, alcohol, other forms of tobacco and habits of chewing betel quid or areca nut have been found as etiological factors for oral precancerous and cancerous lesions.<sup>2,3</sup> Cancers are the increasing cause of mortality in patients with oral mucosal lesions. It can be seen on the lip, buccal mucosa, floor of the mouth, palate as well as on the tongue. Oral cancer is one among the top three types of cancers in India.<sup>3</sup>

Reduced salivary gland function in aging, can predispose to infections of oral mucosa, commonly oral candidiasis.<sup>2,3</sup> Dermatologic diseases have got special attention in oral medicine as oral mucosal lesion (OML) can be the primary clinical feature or sometimes the only sign for various mucocutaneous diseases.<sup>4</sup>

Since there is a paucity of literature in various studies about oral mucosal lesions in the Indian

geriatric population, the present study aimed to document the clinical types of oral mucosal lesions in geriatric population and also to study their distribution with possible etiological factors which will be valuable in planning future oral health studies.

### Materials and Methods

The study was carried out from January 2016 to July 2017 during which a total of 5257 patients above 60 years of age, attending to Dermatology OPD at Medical College, Karnataka were examined and evaluated for oral mucosal lesions. Out of these, 130 patients with oral mucosal lesions enrolled in this study. Those with medical emergencies like burns, corrosive lesions and trismus grade 3 were excluded from the study. This study was approved by the Institutional Ethical committee.

A detailed medical history including demographic data, presence of oral mucosal lesions, medical disorders, medications used, dentures and risk habits (smoking, alcohol, chewing of betel quid, and other forms of tobacco use) were documented.

Clinical evaluation including anatomical location, morphology and extension of the lesion were done with assessment of any etiological factors. In relevant cases, necessary investigations like gram stain, KOH mount, Wood's lamp examination and biopsy for histopathological examination and immunofluorescent techniques were done to establish the definitive diagnosis.

The data thus documented were analyzed by the SPSS 22 version software. Chi-square test was used as test of significance for qualitative data (P < 0.05 were considered as statistically significant).

**Result**

In the present study after screening 5257 elderly patients above 60 years, 130 patients with oral mucosal lesions were enrolled for the study, showing a prevalence of 2.47%. Majority of the patients 71%, were in the age group of 60-69 years, followed by 24% in the age group of 70-79 years, 5% in the age group of 60-69 years and there was no cases above 90 years. Males were marginally more affected (56.2%) than females (43.8%).

In the present study, the commonest site involved was buccal mucosa (58%). Distribution of oral mucosal lesions is mentioned in table 1.

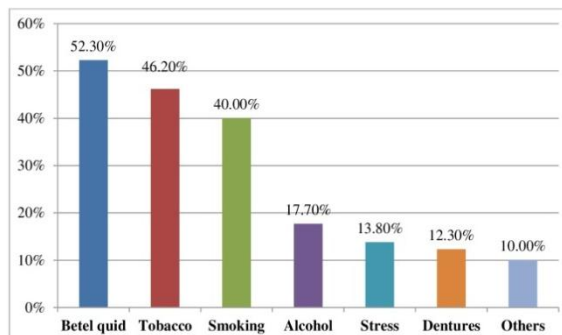
**Table 1: Distribution of oral mucosal lesions**

Anatomical Location*	Number of Cases	Percentage
Buccal mucosa	75	58%
Labial mucosa	19	15%
Lips	15	12%
Tongue	38	29%
Hard palate	11	8%

\*more than one anatomical location may be involved.

In the present study, the predominant risk factors (Fig.1) were betel quid chewers (52.3%), closely

followed by other forms of tobacco (46.2%), smoking (40%) and alcohol (17.7%). Less common were denture wearing (12.3%), stress (13.8%) and others like drug intake and habitual hot spicy foods (10%). Most of the patients had more than one risk habit for the development of oral mucosal lesions. Smoking was the most common risk factor in males. Followed by use of other forms of tobacco and betel quid chewing. Whereas in females, betel quid chewing followed by other forms of tobacco usage and stress were the commonly associated risk factors elicited.



**Fig. 1: Risk factors observed in the study population**

Gender wise distribution of different risk factors observed in the present study population are detailed below in table 2.

**Table 2: Gender wise distribution of risk factors in study population**

Risk factors	Gender				P value
	Male		Female		
	Number	Percentage	Number	Percentage	
Smoking	51	69.9%	1	1.8%	<0.001*
Alcohol	19	26.0%	4	7.0%	0.005*
Tobacco	33	45.2%	27	47.4%	0.806
Betel quid	33	45.2%	35	61.4%	0.067
Dentures	7	9.6%	9	15.8%	0.286
Stress	12	16.4%	6	10.5%	0.333
Others	7	9.6%	4	7.0%	0.279

As mentioned in table 3, most frequent observed etiology for oral mucosal lesions in the present study population were malignancy (25.4%) followed by dermatological (19.2%), premalignant and infectious etiology (16.9%). Less commonly observed were aphthous ulcers (10%), inflammatory (4.6%), drug induced mucositis (3.8%), developmental (2.3%) and systemic (0.8%).

**Table 3: Etiological classification of oral mucosal lesions in study population**

Classification of Various Etiologies		
	Number	Percentage
Malignant	33	25.4%
Dermatological	25	19.2%
Infective	22	16.9%
Premalignant	22	16.9%
Aphthous ulcers	13	10%
Inflammatory	6	4.6%
Drug induced mucositis	5	3.8%

Developmental	3	2.3%
Systemic	1	0.8%

Based on clinical and histopathological evaluation, each diagnosis were subdivided into their clinical types (Table 4).

**Table 4: Clinical types of oral mucosal lesions in the study population**

Clinical types	Number	Percentage
Oral Carcinoma 33 (25.4%)		
Squamous cell carcinoma	32	97%
Adenoid cystic carcinoma	1	3%
Oral Candidiasis 16 (12.4%)		
Hypertrophic type	12	75%
Atrophic type	4	25%
Leukoplakia 11 (8.5%)		
Homogenous	8	73%
Speckled	3	27%
Oral Lichen Planus 10 (7.7%)		
Reticular type	7	70%
Atrophic type	2	20%
Actinic type	1	10%
Vitiligo 8 (6.2%)		
Vitiligo vulgaris	2	25%
Mucosal vitiligo	6	75%
Aphthous Ulcer 8 (6.2%)		
Minor aphthous ulcer	6	75%
Major aphthous ulcer	2	25%
Herpes Simplex 7 (5.4%)		
Herpes labialis	7	100%
Pemphigus 4 (3.1%)		
Pemphigus vulgaris	3	75%
Pemphigus foliaceus	1	25%
Cheilitis 2 (1.5%)		
Granulomatous cheilitis	1	50%
Actinic cheilitis	1	50%
Others		
Oral Submucous Fibrosis	10	7.7%
Drug Induced Mucositis	6	4.6%
Smoker's Melanosis	4	3.1%
Fissured Tongue	3	2.3%
Fordyce Spot	2	1.5%
Geographic Tongue	2	1.5%
Angina bullosa haemorrhagica	1	0.8%
Melanoplakia	1	0.8%
Discoïd Lupus Erythematosus	1	0.8%
Steven Johnson Syndrome	1	0.8%
Systemic Lupus Erythematosus	1	0.8%
Erythroplakia	1	0.8%

Most frequent oral mucosal lesion (OML) in the present study population was malignancy. Out of 33 oral carcinoma, majority (32 cases) were diagnosed as squamous cell carcinoma and other one case was adenoid cystic carcinoma. Frequently involved site of oral carcinoma was buccal mucosa (85%), followed by tongue (12%) and lips (3%).

Oral candidiasis was the second most common OML found in the present study. Hypertrophic type of oral candidiasis was the most common clinical type (75%). Tongue was the most frequently involved site.

Leukoplakia (8.5%) was the common premalignant condition followed by oral submucous fibrosis (7.7%) with a significant association with smoking and alcohol.

Malignant and premalignant lesions were frequently associated with betel quid chewing, other forms of tobacco use, alcohol and smoking. There was significant difference in oral mucosal lesions among smokers and alcoholics (p values were 0.019 and 0.001 respectively).

## Discussion

In general population, oral mucosal lesions are a common clinical findings representing a wide spectrum of conditions, ranging from benign physiological entities to dysplasia and squamous cell carcinoma. Though the prevalence of oral mucosal lesions in general population has been documented based on clinical evaluation in other parts of the world like Turkey<sup>5</sup> and Yemen,<sup>1</sup> limited information is available in rural or semi-urban population of India.<sup>6,7</sup>

In present study after screening 5257 patients above 60 years, 130 patients with oral mucosal lesions were enrolled for the study. The prevalence of oral mucosal lesions in the study population was 2.47% which is consistent with other study (2.2%).<sup>5</sup> The prevalence rates of oral mucosal lesions varies with different geographical, risk habits, genetic factors and sociodemographic characteristics of the study populations.

Similar to few other studies, in the present study mean age of study population was  $65.64 \pm 6.1$  years.<sup>1,2</sup> Majority of the subjects were in the age group 60-69 years (70.8%), followed by 70-79 years (24.6%). This may be because in advancing age due to certain medical reasons, most of them quit oral risk habits like smoking and habitual betel chewing as a result, the incidence of oral mucosal lesions will decrease significantly. However above 70 years age group (52%) showed the highest incidence in Bahia study.<sup>8</sup>

In concordance with various other studies, a male preponderance of 56.2% was seen in the present study whereas similar study in elderly Venezuelan population, females were commonly affected than males.<sup>1, 2, 9</sup> Gender differences in the occurrence of oral mucosal lesions might be attributed to the higher prevalence of oral risk habits among males in this study population.

In the present study, the predominant risk factors were betel quid chewers (52.3%), use of other forms of tobacco (46.2%), smoking (40%) and alcohol (17.7%) followed by denture wearing (12.3%), stress (13.8%) and others like history of drug intake and habitual hot spicy foods (10%). This is consistent with data reported by other studies.<sup>1, 2, 6, 10</sup> Most of the patients had more than one risk habit for the development of oral mucosal lesions. Smoking was the most common risk factor in males, followed by use of other forms of tobacco and betel quid chewing. But in females, betel and areca nut chewing followed by other forms of tobacco usage and stress were the common risk factors elicited. There was significant difference in risk factors between males.

The present study showed smoking beedi is a significant early indicator to develop oral mucosal lesions such as oral carcinoma (59%), leukoplakia (54%), oral submucous fibrosis (36%) and smokers melanosis (4%), with duration and frequency of habits also plays an important role in causation of oral mucosal lesions which is supported by other studies.<sup>2, 10, 11</sup>

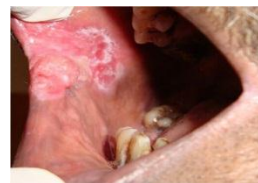Females had chewing habits more than smoking. Habitual betel and areca nut chewers had more prevalence (46%) of oral submucous fibrosis compared to others. During betel quid chewing, endothelial damage may be induced by areca nut components and leading to the pathogenesis of oral submucous fibrosis, periodontitis, and endothelial dysplasia which was supported by few other studies.<sup>3, 11, 12</sup> 60% females gave the history of eating supari (plain areca nut) whereas 49% females gave the history of using tobacco along with betel quid. Women in many rural areas believe that tobacco has many useful medicinal properties in getting rid of foul smell, curing toothache, controlling morning sickness and maintaining oral hygiene.<sup>13</sup>

Among various etiologies encountered in this study, malignancy 25.4%, dermatological conditions 19.2%, infective and premalignant etiologies 16.9% were more common. Less common were aphthous lesions 10%, inflammatory lesions 4.6%, drug induced mucositis 3%, and others 3%.

Out of total 130 patients, 33 were diagnosed with oral carcinoma, in which 32 (96.9%) patients had squamous cell carcinoma and only one case presented with adenoid cystic carcinoma, similar to another study.<sup>11</sup>

The incidence of oral squamous cell carcinoma peaks between the fifth and seventh decades of life.<sup>12</sup> With prolongation of life expectancy, however, the incidence of malignancy in elderly patients is also increasing. This explains the involvement of predominant age group between 61 and 69 years of age in this study.

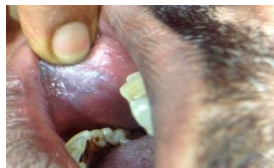Buccal mucosa was the commonest site of involvement (Fig. 2) in the present study population (85%) which was in consistent with other study.<sup>12</sup> This finding can be attributed to the oral risk habits of chewing betel quid and tobacco.



**Fig. 2: Ulceroproliferative squamous cell carcinoma on buccal mucosa**

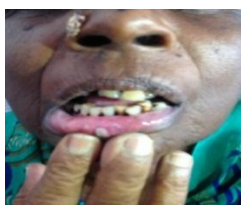A total 25 cases (19.2%), out of 130 patients with oral changes had dermatological disorders. Most frequent dermatological disorder was oral lichen planus

observed in 10 patients (7.7%), with commonly seen clinical type as reticular type (70%), (Fig. 3) followed by atrophic type(20%) and erosive – ulcerative type(10%). This was in consistent to other study.<sup>13</sup> Four cases showed concomitant skin and nail changes.

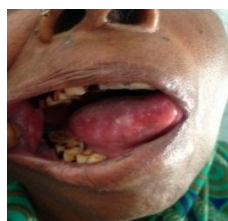

**Fig. 3: Reticular lichen planus on buccal mucosa**

Vitiligo involving oral mucosa observed in eight cases (6%) with a significant female predilection and vermillion border of lips is commonly involved similar to other study.<sup>14</sup> Four vesiculobullous cases with oral involvement were diagnosed among which three were pemphigus vulgaris and one was pemphigus foliaceus. The common presentation of oral mucosal lesions in vesiculobullous conditions were of erosive and ulcerative types (Fig. 4a & 4b), similar to earlier study.<sup>15</sup>

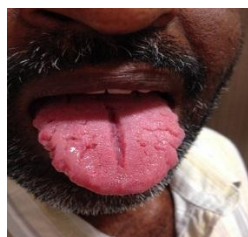

**Fig. 4a : Bullous eruption on lower labial musosa**



**Fig. 4b: Erosive lesions on lateral aspect of tongue**

In the present study, two patients with psoriasis showed fissured tongue (Fig. 5) which are already reported in few other studies.<sup>16</sup> Even though strong correlation suggested, these lesions are not pathognomonic feature of the disease.



**Fig 5: A psoriasis case presented with fissured tongue**

One case of Steven Johnson Syndrome with ocular, oral, cutaneous and genital lesions also observed. Patient showed ulcerative lesions over lips, labial mucosa, buccal mucosa and tongue which is consistent to similar study.<sup>17</sup>

One female systemic lupus erythematosus case with typical malar rash, ulcerative lesions over lips, labial mucosa and tongue was screened associated with joint pain, respiratory tract infection similar to earlier reports.<sup>4,18</sup>

One 80 year old female patient presented with ulcerative lesion over lower lip associated with burning sensation and histological features were consistent with that of discoid lupus erythematosus which is similar to other studies.<sup>4,18</sup>

Total 22 cases of premalignant conditions were diagnosed with most common etiologies being leukoplakia followed by oral submucous fibrosis. In the present study, premalignant conditions showed association with smoking and use of other forms of tobacco with a significant male preponderance. This result was supported by few other studies.<sup>3, 11,19</sup>

Other less observed were aphthous ulcer (6%), herpes infection (5%), drug induced mucositis (5%), smokers melanosis (3%), geographic tongue (2%), Fordyce spot (2%), cheilitis (2%), melanoplakia (2%), angina bullosa hemorrhagica (1%).

## Conclusion

This study enhances the various oral mucosal lesions in geriatric population and also their distribution with possible causative factors which will be valuable in planning future oral health studies. The study also highlights the importance of early diagnosis of oral precancerous conditions before it develops into malignancy.

## References

1. Patil S, Doni B, Maheshwari S. Prevalence and distribution of oral mucosal lesions in a geriatric Indian population. *Can Geriatr J* 2015;18:11-4.
2. Al-Maweri SA, Al-Jamaei AA, Al-Sufyani GA, Tarakji B, Shugaa-Addin B. Oral mucosal lesions in elderly dental patients in Sana'a, Yemen. *J IntSoc Prevent Communit Dent* 2015;5:12-9
3. Varshitha. Prevalence of Oral Cancer in India. *J Pharm. Sci. & Res.* 2015; 7:845-848. Available from www. Jpsr.pharmainfo.in.
4. Suliman NM, Astrom AN, Ali RW, Salman H, Johannessen AC. Oral mucosal lesions in skin diseased patients attending a dermatologic clinic: a cross-sectional study in Sudan. *BMC Oral Health* 2011;11:24.
5. Cebeci AR I, Gulşahi A, Kamburoglu K, Orhan BK, Oztas B. Prevalence and distribution of oral mucosal lesions in an adult turkish population. *Med Oral Patol Oral Cir Bucal* 2009;14:272-277.
6. Mathew AL, Pai KM, Sholapurkar AA, Vengal M. The prevalence of oral mucosal lesions in patients visiting a dental school in Southern India. *Indian J Dent Res* 2008;19:99-103.

7. Byakodi R, Shipurkar A, Byakodi S. Prevalence of oral soft tissue lesions in sangli, India. *J Community Health* 2011;36:756-759.
8. Souza S, Alves T, Santos J, Oliveira M. Oral Lesions in Elderly Patients in Referral Centers for Oral Lesions of Bahia. *Int Arch Otorhinolaryngol.* 2015;19:279-85.
9. Mujica V, Rivera H, Carrero M. Prevalence of oral soft tissue lesions in an elderly venezuelan population. *Med Oral Patol Oral Cir Bucal.* 2008;13:270-4.
10. Saraswathi TR, Ranganathan K, Shanmugam S, Sowmya R, Narasimhan PD et al. Prevalence of oral lesions in relation to habits: Cross-sectional study in South India. *Indian J Dent Res* 2006;17:121.
11. Zhang X, Reichert PA. A review of betel quid chewing, oral cancer and precancer in Mainland China. *Oral Oncol* 2007;43:424-430.
12. Khandekar PS, Bagdey PS, Tiwari RR. Oral cancer and some epidemiological factors: a hospital based study. *Indian J Community Med* 2006;31:157-159.
13. Carbone M., Arduino P.G., Carrozzo M., Gandolfo S, Argiolas MR, Bertolusso G, et al. Course of oral lichen planus: a retrospective study of 808 northern Italian patients. *Oral Dis* 2009;15:35-243.
14. Nagarajan A, Masthan MK, Sankar LS, Narayanasamy AB, Elumalai R. Oral manifestations of vitiligo. *Indian J Dermatol* 2015;60:103.
15. SM Simi, G Nandakumar and TS Anish. White Lesions in the Oral Cavity: A Clinicopathological Study from a Tertiary Care Dermatology Centre in Kerala, India. *Indian J Dermatol* 2013; 58:269-274.
16. Khan S, Zaheer S, Gupta N D. Oral psoriasis: A diagnostic dilemma. *Eur J Gen Dent* 2013;2:67-7.
17. Hirapara HN, Patel TK, Barvaliya MJ, Tripathi C. Drug-induced Stevens-Johnson syndrome in Indian population: A multicentric retrospective analysis. *Niger J Clin Pract* 2017;20:978-83.
18. Annegret Kuhn, Gisela Bonsmann, Hans-Joachim Anders, Peter Herzer, Klaus Tenbrock, Matthias Schneider. The diagnosis and treatment of systemic lupus erythematosus. *DtschArzteblInt* 2015;112:423-32.
19. Pratik P, Desai VD. Prevalence of habits and oral mucosal lesions in Jaipur, Rajasthan. *Indian J Dent Res* 2015;26:196-9.