

Evaluation of efficacy and safety of intense pulse light (IPL) therapy in the treatment of facial acne vulgaris

M R Swaroop^{1,*}, Priyanka Kumari², B.D. Sathyanarayana³, Yogesh D⁴, Aneesa Sajeed⁵

¹Associate Professor, ^{2,5}Post Graduate, ³HOD & Professor, ⁴Assistant Professor, Dept. of Dermatology, Adichunchanagiri Institute of Medical Sciences, B.G. Nagara, Karnataka, India

***Corresponding Author:**

Email: mrswaroop79@gmail.com

Abstract

Introduction: Acne vulgaris is a self-limiting, chronic inflammatory disorder of pilosebaceous follicle seen commonly among young adults with significant psychological and social impact. Multiple topical and systemic therapies targeting various pathogenic factors of acne are available, in spite of which patients are unable to achieve adequate and long term control of acne. Therefore, there is a need for newer therapeutic modalities that are more effective, convenient and safe. In this regard, one of the emerging treatment modalities is intense pulse light (IPL) therapy which meet the need for novel acne treatment.

Objectives: To evaluate the efficacy and safety of intense pulse light (IPL) therapy in the treatment of facial acne vulgaris.

Materials and Methods: A total of 30 patients in age group of 18- 40 years with facial acne vulgaris meeting the defined inclusion and exclusion criteria were enrolled in this study after taking an informed consent and approval of institutional ethical committee. All the patients with facial acne vulgaris grade 1-4 were subjected to monotherapy with IPL. Conversion fluence of 10 J and 410 nm cut off filter was used at first sitting. IPL was administered weekly for 6 weeks, and the fluence was increased by 1 J every session. Acne severity assessment was done at initial visit (week 0) and at the end of last treatment session (week 6) based on Michaelssons acne severity index. Also at the initial visit, at each sitting and at the end of final treatment session (6 sessions), lesions count (counting the number of comedones, papules, pustules, cysts and nodules) were undertaken. Percentage reduction in the number of lesions were calculated at each visit and at end of final treatment session (6th session) and graded as mild (0–25%), moderate (26–50%), good (51–75%), and excellent (76–100%) improvement relative to baseline.

Results: At the end of 6 treatment sessions (6 weeks), the mean percentage reduction of non-inflammatory, inflammatory and total lesion counts were 60.2%, 80.4%, 74.1% relative to baseline respectively. Mean Michaelssons acne severity index at baseline (0 week) was 50.83 and at the end of six treatment sessions was 10.20. The improvement in acne severity score was found to be statistically significant ($p=0.000$). No significant adverse effects were noticed.

Conclusion: The results of this study show that IPL is effective and safe for management of facial acne vulgaris grade 1 – 4 with minimal reversible side effects.

Keywords: Acne vulgaris, Intense pulse light, Non-inflammatory lesions (comedones), Inflammatory lesions (Papules, pustules, Nodules and cysts), Michaelssons acne severity index.

Introduction

Acne vulgaris is one of the most common skin diseases in adolescence and adults; affecting more than 85% of adolescents.¹ Acne can cause significant psychosocial effects including embarrassment, frustration, low self-esteem, loss of confidence and depression. Moreover, severe acne can result in permanent scarring and facial disfigurement which further adversely affects the quality of life of patients.² Acne vulgaris is a multifactorial disease of pilosebaceous units; pathogenic factors being increased sebum production, altered keratinisation of ductal keratinocytes, proliferation of Propionibacterium acnes (P. acnes) and inflammatory signaling.³ Despite continued use of conventional topical and systemic therapies targeting various pathogenic factors, patients are unable to achieve adequate and long term control. There are several limitations to conventional approach in treatment of acne, like antibiotic resistance, hypersensitivity, limited long-term efficacy, poor response and potential side effects of drugs like isotretinoin namely flare up of acne, photosensitivity, dryness, psychological side effects, teratogenicity etc.⁴

Therefore, there is a need for newer therapeutic modalities that are more effective, convenient and safe. In this regard, one of the emerging treatment modalities which meets the need for novel acne treatment is intense pulsed light (IPL) therapy. In spite of IPL therapy in acne gaining popularity in recent years with respect to long term efficacy, safety, convenience and being minimally invasive, there is paucity of such studies in the Indian population. Hence we conducted the present study to evaluate the efficacy and safety of IPL in the treatment of facial acne vulgaris.

Materials and Methods

The present study was conducted in Department of Dermatology, Venereology and Leprosy, Sri Adichunchanagiri Hospital and Research Centre, B.G. Nagara, on an out-patient basis over a period of 18 months. After obtaining approval from Institutional ethical committee and an informed oral and written consent explaining the nature of treatment, a total of 30 patients between the age group of 18-40 years with facial acne vulgaris grade I - IV were enrolled in the study. Patients who had taken oral isotretinoin in the

last 6 month or any other photosensitive medications, patients who had used topical antibiotics, topical retinoids and were on oral antibiotics within the past 4 weeks were excluded. All patients were subjected to monotherapy with IPL (Zigma hp IPL with inbuilt cooling, DermaIndia). Test dose of IPL was given on the flexor aspect of left forearm before starting the therapy. A dose of 10 J fluence and 410 nm cut-off filter was used. The area was observed for any erythema or burning sensation. Patients who tolerated the test dose were taken up for the study. Face was first cleansed with a mild cleanser. Patient's eyes were protected with protective goggles. A layer of 2-5 mm thick cooling gel was applied to the treatment area before the shot to protect the epidermis from thermal injury and to aid in delivering the light uniformly on to the skin surface. To begin with, by convention fluence of 10 J was used for the treatment on the face and 410 nm cut off filter was used for the study. IPL was administered weekly for 6 weeks, and the fluence was increased by 1 J every session. The following IPL parameters were implemented during the study period: auto mode, skin type IV and V, pulse width 4-5 ms, pulse delay 10 ms. After treatment, cooling gel was wiped off with cotton soaked in cold water and ice pack was applied for 5 minutes to alleviate discomfort and to minimize swelling. Patients were advised to apply broad-spectrum sunscreen, emollients and to avoid sun exposure for 48 hours post treatment. Thereafter, patients were advised to use a broad spectrum sunscreen during the course of treatment.

Clinical evaluation - Acne severity assessment was done at initial visit (week 0) based on Michaelsons acne severity index, according to which number of comedones, papules, pustules, nodules and cystic lesions were counted. Severity index was taken as 0.5 for comedones, 1 for papules, 2 for pustules, 3 for infiltrated lesions and 4 for cystic lesions. Multiplying number of each type of lesion with its severity index and adding the score together gave the final score [Severity index $= (0.5 \times n) + (1 \times n) + (2 \times n) + (3 \times n) + (4 \times n)$, where n denotes number of lesion].⁵ Patient's acne severity was assessed again at the end of final treatment session (6 sessions). In addition, at the initial visit, at each sitting and at the end of last treatment session (6 sessions), lesion count (counting the number of comedones, papules, pustules, cysts and nodules) was undertaken. Percentage reduction in the number of lesions was calculated at each visit and at end of last treatment session (6 sessions) and graded as mild (0–25%), moderate (26–50%), good (51–75%) and excellent (76–100%) improvement relative to baseline. Standardized digital photos of each patient (after taking informed consent) was taken prior to starting a treatment session and at every visit. Any adverse events were recorded in detail at each treatment. Any post IPL erythema was treated with topical steroid antibiotic cream provided by the investigator.

The collected information was transferred to SPSS version 20.0 and analyzed accordingly. ANOVA test was applied for calculating mean lesion count. Paired sample t test was done for calculating the improvement in acne severity score. The p value < 0.05 was taken as significant.

Results

In this study, 30 patients with acne vulgaris were recruited. Majority of patients (76.7%) were in the age group between 18-25 years. The mean age of patients with acne vulgaris was 23.2 years. Male to female ratio was 1:1. Majority of patients with acne vulgaris were students (70%). Majority (63.3%) of the subjects had Fitzpatrick's skin type IV followed by 36.7% of patients having Fitzpatrick's skin type V. On clinical examination, majority of patients had acne of grade II severity (46.7%) followed by grade III (36.7%). Patients had progressive decrease in the mean lesion count of comedones, inflammatory lesions and total lesions (inflammatory lesions & comedones) at the end of each treatment session with IPL (6 sessions) which was statistically significant (Table 1, 2, 3). At the end of six treatment sessions (week 6), 3 patients (10.0%) had excellent non inflammatory lesion clearance (>75%), 16 patients (53.3%) had good non inflammatory lesion clearance (51-75%), 9 patients (30.0%) had moderate non inflammatory lesion clearance (25%-50%), 2 patients (6.7%) had mild non inflammatory lesion clearance (<25%) (Fig. 1). At the end of six treatment sessions (week 6), 27 patients (90%) had excellent inflammatory lesion clearance (>75%), 3 patients (10.0%) had good inflammatory lesion clearance (51-75%) (Fig. 2). At the end of six treatment sessions (week 6), 17 patients (56.7%) had excellent total lesion clearance (>75%), 13 patients (43.3%) had good total lesion clearance (51-75%) (Fig. 3). At the end of 6 treatment sessions (6 weeks), the mean percentage reduction in non-inflammatory, inflammatory and total lesion count was 60.2%, 80.4% and 74.1% respectively from baseline (Fig. 4, 5, 6). Mean Michaelsons acne severity index at baseline (0 week) was 50.83 and at the end of six treatment sessions was 10.20. The improvement in acne severity score was found to be statistically significant ($p=0.000$). Percentage reduction in acne severity score at the end of six treatment session was 79.8% from base line (Table 4). No significant side effects were observed however two patients reported mild erythema after the third sitting of IPL which was treated and it resolved.

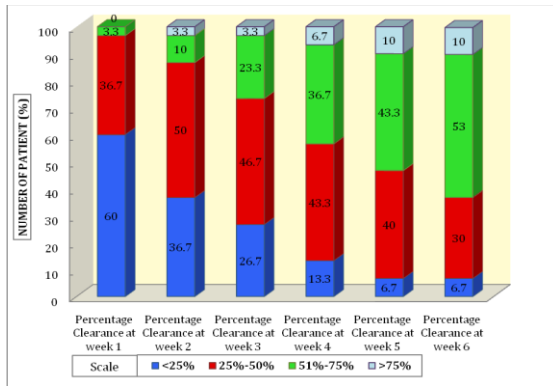


Fig. 1: Percentage clearance of non-inflammatory (comedones) lesions after each session of IPL

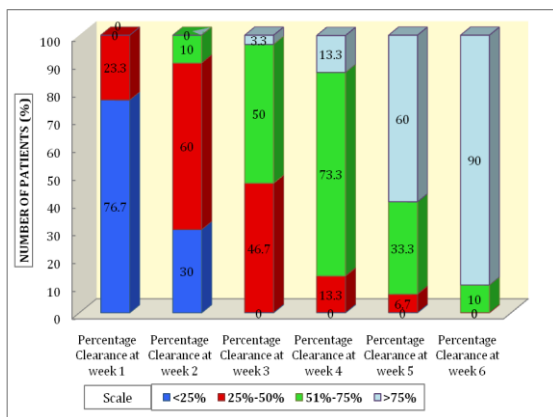


Fig. 2: Percentage clearance of inflammatory lesions after each session of IPL

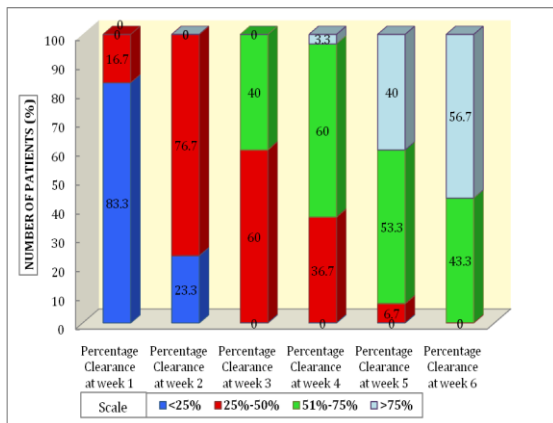


Fig. 3: Percentage clearance of total lesions (inflammatory and non-inflammatory) after each session of IPL

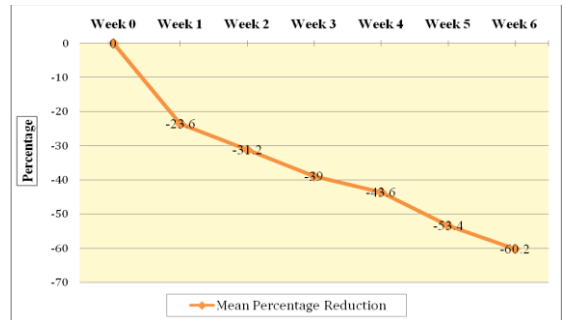


Fig. 4: Mean percentage reduction in non-inflammatory lesion count at the end of each session of IPL

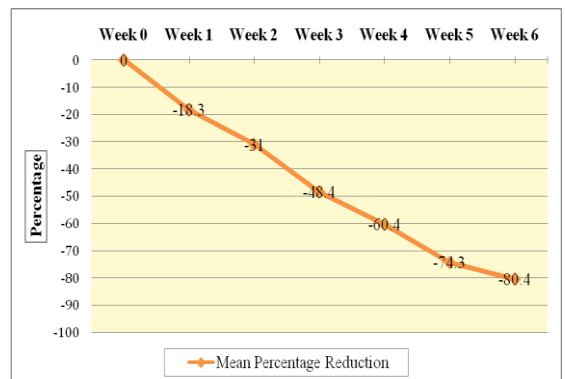


Fig. 5: Mean percentage reduction in inflammatory lesion count at the end of each session of IPL

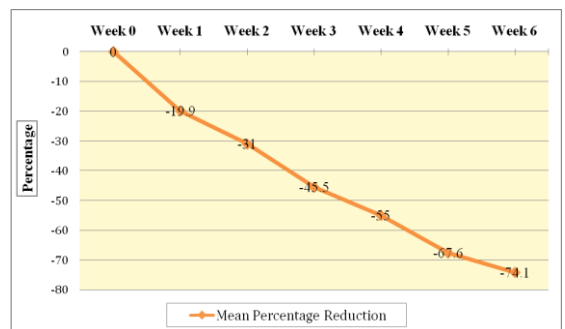


Fig. 6: Mean percentage reduction in total lesion count (inflammatory and non-inflammatory) at the end of each session of IPL

Table 1: Mean lesion count of non-inflammatory (comedones) lesions at 0 week (baseline) and at end of each treatment session with IPL

	Number	Mean	Std. Deviation	Sig.
Non-inflammatory lesionscount at (Week 0)	30	14.00	11.974	
Non-inflammatory lesions count after 1st treatment session (Week 1)	30	10.70	8.840	.000
Non-inflammatory lesions count after 2 nd treatment session (Week 2)	30	9.63	8.888	.000

Non-inflammatory lesions count after 3 rd treatment session (Week 3)	30	8.53	8.593	.000
Non-inflammatory lesions count after 4 th treatment session (Week 4)	30	7.93	9.044	.000
Non-inflammatory lesions count after 5 th treatment session (Week 5)	30	6.53	7.026	.000
Non-inflammatory lesions count after 6 th treatment session (Week 6)	30	5.57	5.667	.000

Table 2: Mean lesion count of inflammatory lesions at 0 week (baseline) and at the end of each treatment session with IPL

	Number	Mean	Std. Deviation	Sig.
Inflammatory lesions count at (Week 0)	30	30.83	13.654	
Inflammatory lesions count after 1 st treatment session (Week 1)	30	25.20	11.146	.000
Inflammatory lesions count after 2 nd treatment session (Week 2)	30	21.27	9.425	.000
Inflammatory lesions Count after 3 rd treatment session (Week 3)	30	15.90	7.967	.037
Inflammatory lesions Count after 4 th treatment session (Week 4)	30	12.20	7.232	.029
Inflammatory lesions count after 5 th treatment session (Week 5)	30	7.93	5.919	.01
Inflammatory lesions count after 6 th treatment session (Week 6)	30	6.03	4.951	.03

Table 3: Mean lesion count of total lesions (inflammatory & non-inflammatory) at 0 week (baseline) and at end of each treatment session with IPL

	Number	Mean	Std. Deviation	Sig.
Total Lesions count at (Week 0)	30	44.83	14.355	
Total lesions count after 1 st treatment session (Week 1)	30	35.90	11.382	.001
Total lesions count after 2 nd treatment session (Week 2)	30	30.90	9.932	.001
Total lesions count after 3 rd treatment session (Week 3)	30	24.43	10.013	.003
Total lesions count after 4 th treatment session (Week 4)	30	20.13	10.715	.003
Total lesions count after 5 th treatment session (Week 5)	30	14.50	9.471	.001
Total lesions count after 6 th treatment session (Week 6)	30	11.60	7.775	.005

Table 4: Michaelssons acne severity index at week 0 (baseline) and at the end of 6th treatment session of IPL

	Number	Mean	Std. Deviation	Sig.	Percentage Reduction
Michaelssons scoring at week 0	30	50.83	24.9414256	0.000	79.8%
Michaelssons scoring at 6 th week	30	10.20	6.7333447		

Discussion

Many light based and laser modalities are now available for the treatment of acne vulgaris.^{3, 6-8} One of the emerging treatment modalities which is effective and safe for treatment of acne vulgaris is Intense pulsed

light therapy.⁹ IPL devices are non-laser high intensity light sources that make use of a high output flashlamp to produce a wavelength output of noncoherent light, usually in the range of 400 to 1200 nm.¹⁰ IPL in acne vulgaris works by photochemical, photothermal and

photo-immunological process.^{11,12} The photochemical reaction seen in acne vulgaris lesions is through its action on porphyrins produced by the *P. acnes* bacteria themselves. Protoporphyrin IX (PpIX) and coproporphyrin III are the two porphyrins produced. These porphyrins have an absorption spectrum in the near ultraviolet (UV) and visible spectrum of light. The major absorption peak for these porphyrins is at 415 nm, in the blue range of the visible light spectrum, known as the Soret band. A second absorption peak is seen at 630 nm corresponds to red light. Once the porphyrin exposed to the visible light, it becomes chemically active and leads to formation of reactive oxygen species, which combines with the cell membrane of *P. acnes* and leads to selective destruction of the bacteria.^{13, 14} In IPL during photothermolysis, the endogenous chromophores in the skin absorb broad spectrum light delivered by IPL which creates enough heat and energy to damage blood vessels supplying sebaceous glands, thus reduce sebum production.¹⁵ Anti-inflammatory effect of IPL is through down regulation of TNF- α and upregulation of transforming growth factor-beta1 (TGF- β 1)/smad signaling.^{16, 17}

In our study the mean lesion count of non-inflammatory (comedones) lesions progressively decreased at the end of each treatment session with IPL (6 sessions). At the end of six treatment sessions, the mean lesion count of non-inflammatory lesions decreased to 5.57 from 14.00 (baseline) which was found to be statistically significant ($p=0.000$) implying that IPL has an effective anticomedogenic property. There was also progressive decrease in the mean lesion count of inflammatory (papules, pustules, nodules and cysts) lesions at the end of each treatment session with IPL (6 sessions). At the end of six treatment sessions, mean inflammatory acne lesion count decreased to 6.03 from 30.83 (baseline) which was found to be statistically significant ($p=0.03$), inferring that IPL is effective for clearance of inflammatory acne lesions as well. However there were no similar studies to compare our results of mean lesion count clearance of non-inflammatory and inflammatory lesions. At the end of six treatment sessions, the mean lesion count of total lesions reduced from 44.83 (at baseline) to 11.60 which was found to be statistically significant ($p=0.005$). Our study results was in concordance with similar study done by Khan WZ et al¹⁸ wherein mean lesion count of total lesions decreased to 7.48 ± 3.34 of their pretreatment value (14.49 ± 2.93) after final treatment session which was statistically significant ($p=0.000$). At the end of six treatment sessions (week 6), 3 patients (10.0%) had excellent non inflammatory lesion clearance (>75%), 16 patients (53.3%) had good non inflammatory lesion clearance (51-75%). In contrary, study conducted by Mohanan S et al;¹⁹ out of 8 patients, five patients had good non inflammatory acne clearance (51%-75%) and three patients had moderate acne clearance (25%-50%) at the end of five treatment

sessions of IPL. In the present study, at the end of six treatment sessions (week 6), 27 patients (90.0%) had excellent inflammatory lesion clearance (>75%), 3 patients (10.0%) had good inflammatory lesion clearance (51-75%). In a similar study conducted by Mohanan S et al;¹⁹ out of 8 patients, two patients had excellent inflammatory acne clearance (>75%) and five patients had good acne clearance (51%-75%) at the end of five treatment sessions of IPL. At the end of six treatment sessions (week 6), 17 patients (56.7%) had excellent total lesion clearance (>75%), 13 patients (43.3%) had good total lesion clearance (51-75%). However, similar study done by Mohanan S et al¹⁹ wherein seven patients had 51-75% reduction in lesion count (good response) and one had moderate response at the end of five treatment sessions; Khan W Z et al¹⁸ reported 6 patients (8%) having excellent response and 33 patients (44%) showing good response at the end of treatment.

At the end of 6 treatment sessions (6 weeks), the mean percentage reduction in non-inflammatory lesion count was 60.2% and inflammatory lesion count was 80.4% from baseline. A study conducted by Kawana S et al²⁰ reported the mean percentage reduction in non-inflammatory acne lesions being 87.1% and the mean percentage reduction in inflammatory acne lesion was 88.3% after five treatment sessions of IPL. In our study at the end of 6 treatment sessions (6 weeks), the mean percentage reduction in total lesion count was 74.1% from baseline. In a similar study done by Mohanan S et al¹⁹ the mean percentage reduction was 64.7% at the end of five treatment sessions.

In present study, mean Michaelsons acne severity index at baseline (0 week) was 50.83 and at the end of six treatment sessions was 10.20. The improvement in acne severity score was found to be statistically significant ($p=0.000$). Percentage reduction in acne severity score at the end of six treatment sessions was 79.8% from base line. In a similar study done by Kumaresan M et al¹³ the mean total acne severity score at the baseline was 49.4 and at the end of four treatment sessions was 25.1 and percentage reduction in acne severity score showed 49.19% reduction from baseline.

There were no major side effects observed. Mild erythema was noted in two patients which resolved with appropriate treatment. However, in study done by Kawana s et al;²⁰ out of 25 patients, twenty patients experienced immediate erythema, nineteen of them reported burning or stinging, which disappeared within a few days. Crusting, bulla formation and hyperpigmentation were observed in four, one and two patients respectively but these resolved within 1 to 2 weeks. Patidar MV et al¹¹ reported itching in forty patients, erythema in two patients, burning sensation in three patients and two patients developed milia.

Conclusion

The results of present study revealed that IPL is effective for both non-inflammatory (comedones) and inflammatory lesions at the end of six treatment sessions which was found to be statistically significant. Side effects observed were not significant. Hence, IPL as monotherapy with wavelength of 410 nm was found to be effective and safe in the management of facial acne vulgaris grade I- IV.

References

1. James WD. Clinical practice. Acne. *N Engl J Med* 2005;352:1463-72.
2. Tan JK. Psychosocial impact of acne vulgaris: evaluating the evidence. *Skin Therapy Lett* 2004;9:1-3.
3. Choi YS, Suh HS, Yoon MY, Min SU, Lee DH, Suh DH. Intense pulsed light vs. pulsed-dye laser in the treatment of facial acne: a randomized split-face trial. *J Eur Acad Dermatol Venereol* 2010;24:773-80.
4. Barikbin B, Ayatollahi A, Younespour SH, Hejazi S. Evaluation of efficacy of Intense pulse light (IPL) system in treatment of facial acne vulgaris: comparison of different pulse duration; a pilot study. *J Lasers Med Sci* 2011;2:67-72.
5. Kubba R, Bajaj AK, Thappa DM, Sharma R, Vedamurthy M, Dhar S et al. Pathogenesis of acne. *Indian J Dermatol Venereol Leprol* 2009;75:Suppl S1:5-9.
6. Haedersdal M, Togsverd-Bo K, Wulf HC. Evidence-based review of lasers, light sources and photodynamic therapy in the treatment of acne vulgaris. *J Eur Acad Dermatol venereol* 2008;22:267-78.
7. Munavalli GS, Weiss RA. Evidence for lasers and light based treatment of acne vulgaris. *Semin Cutan Med Surg* 2008;27:207-11.
8. Rojanamatin J, Choawawanich P. Treatment of inflammatory facial acne vulgaris with intense pulsed light and short contact of topical 5-aminolevulinic acid: a pilot study. *Dermatol Surg* 2006;32:991-96.
9. Elman M, Lask G. The role of pulsed light and heat energy (LHE™) in acne clearance. *J Cosmet Laser Ther* 2004;6:91-5.
10. Pei S, Inamadar AC, Adya KA, Tsoukas MM. Light-based therapies in acne treatment. *Indian Dermatol Online J* 2015;6:145-57.
11. Patidar MV, Deshmukh AR, Khedkar MY. Efficacy of intense pulsed light therapy in the treatment of facial acne vulgaris: Comparison of two different fluences. *Indian J Dermatol* 2016;61:545-9.
12. Faghihi G, Isfahani AK, Hosseini SM, Radan MR. Efficacy of intense pulsed light combined with topical erythromycin solution 2% versus topical erythromycin solution 2% alone in the treatment of persistent facial erythematous acne macules. *Adv Biomed Res* 2012;1:70.
13. Kumaresan M, Srinivas CR. Efficacy of IPL in treatment of acne vulgaris: Comparison of single- and burst-pulse mode in IPL. *Indian J Dermatol* 2010;55:370-2.
14. Lee GS. Inflammatory Acne in the Asian Skin Type III Treated with a Square Pulse, Time Resolved Spectral Distribution IPL System: A preliminary study. *Laser Ther* 2012;21:105-11.
15. Rai R, Natarajan K. Laser and light based treatments of acne. *Indian J Dermatol Venereol Leprol* 2013;79:300-9.
16. Taylor M, Porter R, Gonzalez M. Intense pulsed light may improve inflammatory acne through TNF- α down-regulation. *J Cosmet Laser Ther* 2014;16:96-103.
17. Ali MM, Porter RM, Gonzalez ML. Intense pulsed light enhances transforming growth factor beta1/Smad 3 signaling in acne-prone skin. *J Cosmet Dermatol* 2013;12:195-203.
18. Khan WZ, Butt G, Altaf F. Efficacy and safety of Intense pulsed light in the treatment of mild to moderate acne vulgaris. *J surg Dermatol* 2017;2:152-7.
19. Mohanan S, Parveen B, Malathy PA, Gomathi N. Use of intense pulse light for acne vulgaris in Indian skin - a case series. *Int J Dermatol* 2012;51:473-6.
20. Kawana S, Tachihara R, Kato T, Omi T. Effect of smooth pulsed light at 400 to 700 and 870 to 1,200 nm for acne vulgaris in Asian skin. *Dermatol Surg* 2010;36:52-7.