

Evaluation of the therapeutic effect of PUVA therapy in chronic vitiligo patients

Kandala Bhaskara Narayana

Professor, Dept. of Department of Dermatology, Venereology and Leprosy, MNR Medical College and Hospital, Fasalwadi, Telangana, India

***Corresponding Author:**

Email: kbn.dermatology1955@gmail.com

Abstract

Introduction: Vitiligo is an acquired pigmentary disease, characterized by depigmented macules or patches which distracts the psychosocial behaviour of patients. Various therapeutic modalities have been administered over time with variable outcome. Psoralen followed by irradiation with UV-A (PUVA) is one of the effective treatment methods for chronic vitiligo cases who had failed to react to the other treatment methods.

Aim: To assess the efficacy of therapeutic effect of oral psoralen followed by ultraviolet-A irradiation (PUVA) therapy for chronic vitiligo cases.

Materials and Methods: A total 36 patients of both sexes with acral, acrofacial and generalised vitiligo with more than 20% spread over body, between age group 15-60 years were recruited. 8 MOP tablets are given with empty stomach according to body weight. All cases were undergone to UVA exposure artificial phototherapy chamber starting with a dose of 4 J/m² (Dosage depends on Fitzpatrick skin type) over whole body after 90 min. Clinical response was evaluated as marked response rate.

Results: Generalised vitiligo was seen in 66.6% cases, acral was seen in 16.6% cases, acrofacial was seen in 16.6% cases. Erythema was the common side effect followed by xerosis, pruritus, nausea and vomiting, bulla and burning. The mean duration of treatment was 14.52 months with mean no of sessions is 62.18.

Conclusion: PUVA therapy is a well-established treatment modality for vitiligo with very minimal risk of malignancies and has less side effects like erythema and xerosis. PUVA is safe, effective, and cosmetically acceptable. Generalized vitiligo responded well to the treatment.

Keywords: Psoralen and ultraviolet A (PUVA), Generalised vitiligo, Acral vitiligo, Acrofacial vitiligo.

Introduction

Vitiligo is one of the most common ancient diseases known to mankind characterized by depigmented macules and patches.¹ It is caused by selective destruction of cutaneous melanocytes, which affects both sexes and can be developed at any age. Vitiligo has a prevalence of 0.5%-1%, which impairs the quality of life of a sufferer.²

Vitiligo has multiple treatment modalities including psoralen and ultraviolet A (PUVA) therapy and narrow band ultraviolet B (NB-UVB), topical therapy like topical corticosteroids, topical vitamin D3 analogues and topical calcineurin inhibitors and surgical therapies like split thickness graft and mini grafts, but these are often unsatisfactory.³

Psoralen followed by irradiation with UV-A (PUVA) is one of the well-established treatments for vitiligo. PUVA causes repigmentation by activating inactive melanocytes in the hair root sheath and middle and the lower part of hair follicle.⁴ For effective results PUVA has to be given for a prolonged duration with at least 100-200 sessions at least A days apart, 2-3 times a week. With the reference to above literature, this study was conducted to evaluate the efficacy of therapeutic effect of oral psoralen followed by ultraviolet-A irradiation (PUVA) therapy for chronic vitiligo cases.

Materials and Methods

The present prospective study was conducted in Department of Dermatology, venereology and leprosy

(DVL), MNR Medical College and Hospital during April 2016 to January 2018. A total 36 patients of both sexes between 15-60 years were recruited.

Inclusion Criteria: Cases with acral, acrofacial and generalised vitiligo with more than 20% spread over body were included.

Exclusion Criteria: Cases not willing to participate, with photosensitive skin disorders, with renal dysfunction, pregnancy and in lactation were excluded.

Informed consent was obtained from all the cases. All cases were subjected to detail clinical examination and were examined for pattern of vitiligo, area skin involved, lesions count, lesions colour and mucosal involvement. A complete haemogram and microbial analysis was conducted for regular parameters. Lesions over the body were evaluated with Rule of Nine. Based on the body weight, 8 MOP tablets are given with empty stomach. After 90 minutes cases were allowed to UVA exposure artificial phototherapy chamber starting with a dose of 4 J/m² (Dosage depends on Fitzpatrick skin type) over whole body. Procedure was continued twice a week Started with standard initial dose of 2 J/cm² and was increased 0.5 J/Sq.cm dose depends on subject response.

Clinical response was evaluated as marked response rate, defined as < 25% is mild response, 26%-50% is moderate response, 51%-75% is good response and >75% is marked response in the lesioned area. The data was tabulated and statistical analysis was done by using SPSS statistical software tool.

Results

A total 36 cases (20 males and 16 females) with acral, acrofacial and generalised vitiligo with more than 20% spread over body were considered. Among the cases, generalised vitiligo was seen in 66.6% cases,

acral was seen in 16.6% cases, acrofacial was seen in 16.6% cases. No cases with segmental and focal vitiligo in this study (Table 1).

Table 1: Clinical distribution of type of vitiligo

Type of vitiligo	Total number of cases (n=36)			
	Stable	Progressive	Number	Percentage
Generalized vitiligo	8	16	24	66.67%
Acral vitiligo	2	4	6	16.6%
Acro facial vitiligo	3	3	6	16.6%
Segmental	-	-	-	-
Focal	-	-	-	-

Table 2: Side effects by PUVA (n=36)

Symptoms	Generalised (n=24)		Acral (n=6)		Acrofacial (n=6)	
	Number	Percentage	Number	Percentage	Number	Percentage
Nausea and vomiting	7	19.4%	1	2.7%	2	5.5%
Erythema	13	36.1%	3	8.3%	4	11.1%
Bulla	4	11.1%	-	-	1	2.7%
Xerosis	9	25%	2	5.5%	2	5.5%
Pruritus	10	27.7%	1	2.7%	1	2.7%
Burning	1	2.7%	-	-	1	2.7%
Others	-	-	-	-	-	-

Acute side effects in generalised vitiligo was erythema, pruritus, xerosis followed by nausea and vomiting, bulla and burning. In acral vitiligo group,

erythema, xerosis, pruritus, nausea and vomiting. In acrofacial group, erythema, xerosis, nausea and vomiting, bulla, pruritus and burning (Table 2).

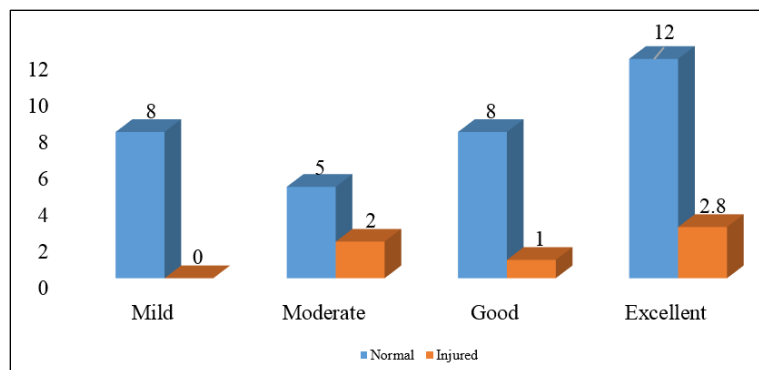


Fig. 1: Relationship between PUVA and physical and chemical injury

Table 3: Overall response of various types of vitiligo to PUVA therapy

Type	Mild response (<25%)	Moderate response (26-50%)	Good response (51-75%)	Marked response (>75%)	No response
Generalized (n=24)	3	4	11	6	-
Acral (n=6)	-	3	3	-	-
Acrofacial (n=6)	1	2	3	-	-

In generalised vitiligo, excellent response was seen in 6 (25%) cases, good response in 11 (45.8%) cases, moderate response in 4 (16.6%) cases and mild response in 3 (12.5%) cases. In acral group, good response was seen in 3 (50%) cases and moderate

response was seen in 3 (50%) cases. In acrofacial group, good response was seen in 3 (50%) cases, moderate response was seen in 2 (33.3%) cases and mild response was seen in 1 (16.6%) case (Table 3).

A total 12 cases had positive family history of vitiligo. Alopecia areata (30.5%) was commonest associated autoimmune disorder followed by hyperthyroidism (13.8%) and hypothyroidism (11.1%) (Fig. 2)

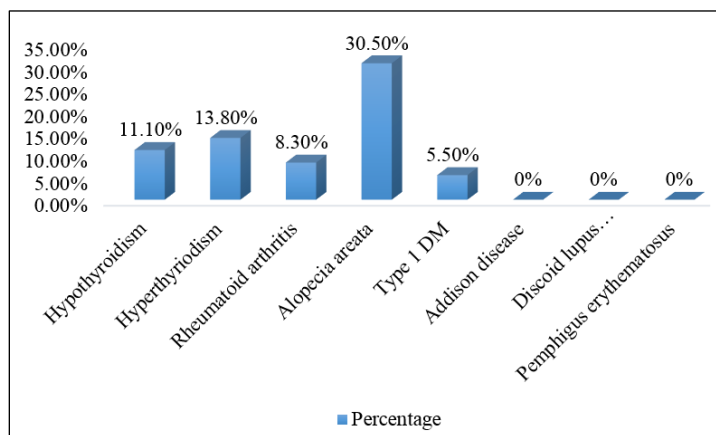


Fig. 2: Associated autoimmune disorders in vitiligo

Table 4: Overall response rate of PUVA therapy in vitiligo cases

Clinical demographics of cases	Mean \pm SD
Age	37.5 \pm 10.82
Duration of disease (months)	98.40 \pm 38.7
% of area involved	31.36 \pm 8.76
No.of sessions	62.18 \pm 32.54
Duration of treatment	14.52 \pm 7.98
Cumulative dose (J/cm ²)	230.4 \pm 126.34
Last visit	21.86 \pm 5.72
Regimentation (50-75%)	17 (47.2%)

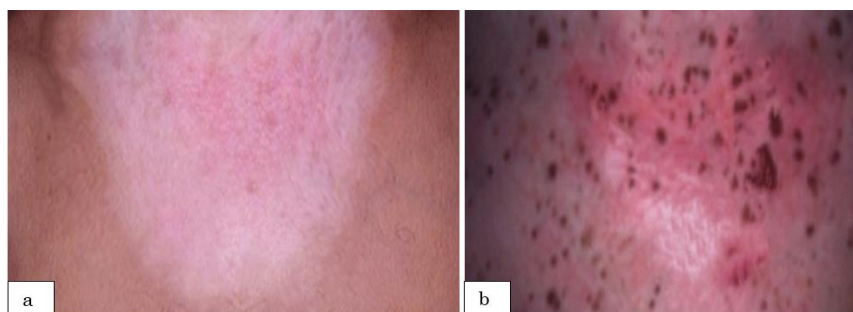

Fig. 3: Effect of PUVA therapy before and after treatment; (a): Before treatment), (b): After treatment

Discussion

Psoralens are synthesized naturally or synthetically. 8-methoxypsoralen (8-MOP) is commonly available oral and topical formulation in India. Psoralen coalesce with epidermal DNA which diminishes DNA replication thus ceases cell cycle. Psoralens and UV radiation also stimulate melanogenesis. In vitiligo, the mode of pigment induction of PUVA is hypothetical. The photoconjugation of psoralens in melanocyte DNA leads to mitosis, replication and proliferation of melanocytes, increased number of melanosomes and their further transfer to keratinocytes. Stimulation of cyclic adenosine monophosphate (cAMP) activity by

PUVA leads to increased synthesis of tyrosine. PUVA also affects immunological processes and may induce a suppressor T cell population and release IL-10 which is important for differentiation and activation of T regulatory cells that may suppress the auto-immune stimulus responsible for melanocyte destruction. PUVA also induces basic fibroblast growth factor (bFGF) and hepatocyte growth factor, which may aid in regrowth and migration of follicular melanocytes to the basal layer of skin.^{5,6}

Vitiligo is an auto inflammatory idiopathic skin condition affecting 1% population, with symptoms of depigmented macules and patches.¹ The present study was conducted to evaluate the efficacy of therapeutic

effect of oral psoralen followed by PUVA therapy for vitiligo cases. A total 36 cases with acral, acrofacial and generalised vitiligo with more than 20% spread over body were considered.

Among the cases, generalised vitiligo is seen in 66.6% cases, acral was seen in 16.6% cases, acrofacial was seen in 16.6% cases. No cases with segmental and focal vitiligo in this study (Table 1). Study by Serkan Yazici et al, stated generalised vitiligo (16 cases) was common subtype followed by acrofacial (6 cases) and focal vitiligo (4 cases).⁷ Study by Hari Kishan Kumar Y et al, stated that 59.3% cases had generalized vitiligo, 30% cases had acral/acrofacial type, 5.3% had focal and 5.3% had segmental type of vitiligo.⁸

In the present study erythema was the common side effect followed by xerosis, pruritus, nausea and vomiting, bulla and burning (Table 2). Serkan Yazici et al, in his study not observed any side effects except in one case who had reversible erythema.⁷ Hari Kishan Kumar Y et al, in his study stated that 7% cases reported mild erythema, burning, pruritus and 6% cases complained of xerosis.⁸

Due to PUVA therapy, in generalised vitiligo, marked response was found in 25% cases, good response in 45.8% cases, moderate response in 16.6% cases and mild response in 12.5% cases. In acral group, good response was seen in 50% cases and moderate response was seen in 50% cases. In acrofacial group, good response was seen in 50% cases, moderate response was seen in 33.3% cases and mild response was seen in 16.6% case (Table 3).

In this study, the mean age of the patients was 37.5 years, mean duration of disease was 98.40 months and the mean percentage of area affected with vitiligo is 31.36cms. The mean duration of treatment was 14.52 months with mean no of sessions is 62.18. In this study, the mean cumulative dose require to get marked response was 230.4 ± 126.34 J/cm² (Table 4). Study by Hari Kishan Kumar Y et al, stated that lesser number of exposures (51.91) and lesser cumulative dose (46.8 ± 25.2 J/cm²) was enough to achieve 25-75% repigmentation (8). Study by Njoo et al, and other western studies noticed same repigmentation with more number of exposures (76.3 ± 16.7) (9-13). The results of present study is correlating with the other Indian studies which stating that Fitzpatrick type IV and V needs lesser number of exposures than Fitzpatrick type I and II (14-16).

Conclusion

PUVA therapy is a safe, effective and gold standard therapeutic modality for the treatment of vitiligo with minimal side effects. Which has a very good safety profile in Indian skin and have not been reported other side effects and cases of carcinogenesis. PUVA is better than UVB because of deep penetration. In this study, generalized type was best to respond well for the treatment than acral and acrofacial which are

resistant. Erythema was the common side effect followed by xerosis, pruritus, nausea and vomiting, bulla and burning.

References

1. Dutta AK, Dhar S. Vitiligo: Past and present. *Indian J Dermatol.* 2002;47(3):132-40.
2. Stephen O. Kovacs, continuing medical education - vitiligo. *J Am Acad. Dermatol.* 1998;38:647-66.
3. Noor SM, Khurshid K, Mehmood T, Haroon TS. Quality of life in vitiligo patients. *J Pak Assoc Dermatol.* 2004;14:55-8.
4. Halder RM. Childhood vitiligo. *Clin Dermatol.* 1997;15:899-906.
5. Falabella R, Barona MI. Update on skin repigmentation therapies in vitiligo. *Pigment Cell Melanoma Res.* 2008;22:4265.
6. Wu CS, Lan CC, Wang LF, Chen GS, Wu CS, Yu HS. Effects of psoralen plus ultraviolet A irradiation on cultured epidermal cells in vitro and patients with vitiligo in vivo. *Br J Dermatol.* 2007;156:122-9.
7. Serkan Yazici, Berrin Gunay, Emel Bulbul Baskan, Kenan Aydogan, Hayriye Saricaoğlu, Şukran Tunalı. The efficacy of narrowband UVB treatment in pediatric vitiligo: a retrospective analysis of 26 cases. *Turk J Med Sci.* 2017;47:381-384.
8. Y. Hari Kishan Kumar, G. Raghu Rama Rao, K. V. T. Gopal, G. Shanti, K. Veerabhadra Rao. Evaluation of narrow-band UVB phototherapy in 150 patients with vitiligo. *Indian J Dermatol Venereol Leprol.* 2009;75(2):162-166.
9. Scherschun L, Kim JJ, Lim HW. Narrow-band ultraviolet B is a useful and well-tolerated treatment for vitiligo. *J Am Acad Dermatol.* 2001;44:999-1003.
10. Yones SS, Palmer RA, Garibaldinos TM, Hawk JLM. Randomized Double-blind trial of Treatment of Vitiligo: Efficacy of psoralen-UVA therapy vs narrowband-UV-B therapy. *Arch Dermatol.* 2007;143:578-83.
11. Njoo MD, Bos JD, Westerhof W. Treatment of generalized vitiligo in children with narrow-band (TL-01) UVB radiation therapy. *J Am Acad Dermatol.* 2000;42:245-53.
12. Anbar TS, Westerhof W, Rahman AT, Khayyat MA. Evaluation of the effects of NB-UVB in both segmental and nonsegmental vitiligo affecting different body sites. *Photodermatol Photoimmunol Photomed.* 2006;22:157.
13. Gambichler T, Breuckmann F, Boms S, Altmeyer P, Kreuter A. Narrowband UVB phototherapy in skin conditions beyond psoriasis. *J Am Acad Dermatol.* 2005;52:660-70.
14. Kanwar AJ, Dogra S, Prasad D, Kumar B. Narrow-band UVB for the treatment of vitiligo: An emerging effective and welltolerated therapy. *Int J Dermatol.* 2005;44:57-60.
15. Dogra S, Prasad D. Combination of narrow band UVB and topical calcipotriene in vitiligo. *Arch Dermatol.* 2003;139:393.
16. Kanwar AJ, Dogra S. Narrow-band UVB for the treatment of generalized vitiligo in children. *Clin Exp Dermatol.* 2005;30:332-6.

How to cite this article: Narayana KB. Evaluation of the therapeutic effect of PUVA therapy in chronic vitiligo patients. *Ind J Clin Exp Dermatol.* 2018;4(3):237-240.